

# Research Journal of Pharmaceutical, Biological and Chemical Sciences

## Palliative Effect of Piracetam on Valproate Induced Liver Injury.

Shamsher Shrestha, Mandavi Singh, Uttam Shrestha, and Anand Mishra\*

Department of Anatomy, Institute of Medical Sciences, Banaras Hindu University, Varanasi, Uttar Pradesh-221005, India.

### ABSTRACT

Valproic acid is one of the main antiepileptic drug which is a branched chain carboxylic acid used for absence seizures. The depletion of  $\beta$ -oxidation as well as increased synthesis of toxic unsaturated valproic acid derivatives results in severe hepatotoxicity. Piracetam is a nootropic or cognitive enhancing agent which is used to treat cognitive impairment in aging, brain injuries as well as dementia. The objective of the present study is to observe the ameliorative effect of piracetam in valproic acid induced liver injury. Experimental mice were divided into four groups. Group I mice termed as control received distilled water. Group II mice was administered valproic acid at the dose of 500mg/kg/body, group III mice was given piracetam at the dose of 800 mg/kg while group IV mice received both valproic acid and piracetam in the same dose for 6 days. The mice were sacrificed and their liver was collected for histological study. There was marked degeneration and destruction of lamina pattern of hepatocytes as well as reduction in glycogen granules. The intensity of the toxic effects of valproic acid was considerably reduced by piracetam. This shows that piracetam act as a protective agent in Valproic acid induced insult to the liver.

**Key words:** antiepileptic, hepatotoxicity, cytoprotective, glycogen granules

*\*Corresponding author*

## INTRODUCTION

Epilepsy is a chronic neurological disorder which is an important problem from a medical, social and legal point of view [1]. It is the most common serious disorder of brain characterized by recurrent seizures. Valproic acid, a branched chain carboxylic acid, is one of the main antiepileptic drugs used in both generalized and partial epilepsies which is capable of controlling all types of seizures [2,3]. Valproic acid is prescribed in disorder characterized by neuropathic pain, bipolar disorders and migraine prophylaxis [2-4].

VPA is metabolized largely by the liver and is eliminated mainly in the urine, with minor amount in the feces and expired air. In liver it has been reported to interfere in the oxidation of endogenous fatty acids [5,6]. The  $\beta$ -oxidation of long- and medium-chain fatty acids is inhibited by VPA and its unsaturated metabolite, 4-en-VPA [7-9]. This occurs by sequestering coenzyme A (CoA), and by the accumulation of non-acetyl CoA esters, possibly valproyl-CoA [10]. The depletion of  $\beta$ -oxidation as well as increased synthesis of toxic unsaturated Valproic acid derivatives results in severe hepatotoxicity [11,12]. It has been reported that steatosis and necrosis of hepatocyte are the main histopathological changes in liver of albino rat induced by toxic dose of Valproic acid [13]. It alters the liver cell morphology, which was proportional to the period of treatment and also induces fatty degeneration of hepatocyte, swelling and increased number of Kupffer cells. Increasing the time of exposure to the drug produce inflammation of portal tract, albuminous degeneration and necrosis of septa, precirrhotic condition, cirrhosis, degeneration of hepatocyte and glassy eosinophilic homogenous cytoplasm [14].

Piracetam, a cyclic derivative of gamma-aminobutyric acid (GABA), is a nootropic or cognitive enhancing agent which is used to treat cognitive impairment in aging, brain injuries as well as dementia [15,16]. It also improves the function of the neurotransmitter acetylcholine which is implicated in memory processes [17]. It has also been reported that piracetam possesses cytoprotective, antioxidant and antihypoxic protective effects by its mitochondrial membrane stabilizing action and vasodilatory effect [18-21]. However the role of piracetam on the liver parenchyma is yet to be elucidated

## MATERIALS AND METHODS

### Animals

The animals used in this study were female Swiss albino mice (25-30 g), maintained in individual cages with a 12 hr light-dark cycle (lights on from 8:00 to 20:00 hr), under controlled temperature ( $25\pm 2^\circ\text{C}$ ) and humidity in animal house of Department of Anatomy, Institute of Medical Sciences, Banaras Hindu University. Animals were given free access to tap water and food. All experiments were carried out in accordance with the guidelines of the ethical committee of Banaras Hindu University.

## Experimental design and drug treatment

The mice were divided in four different groups with 8 mice in each group. Group II mice were given Valproic acid (Encorate, Sun Pharma, Sikkim) at the dose of 500 mg/kg body weight for 6 days orally via oral gavage needle. Group III mice were administered Piracetam (Neurocetam, Micro labs ltd, Solan, HP) at the dose of 800mg/kg body weight for 6 days through oral route. Group IV mice were given both the Valproic acid (500 mg/kg body weight) and Piracetam (800mg/kg body weight) for same duration. Group I mice termed as control were given same volume of distilled water since the drugs were dissolved in distilled water before administration.

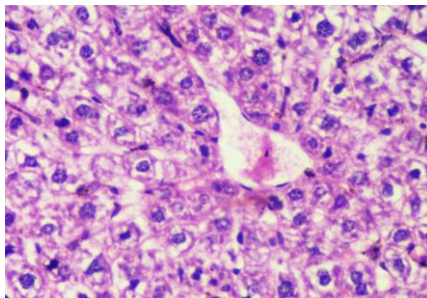
After treatment of the drug, mice in each group was sacrificed by cervical dislocation, their liver was exposed, isolated and fixed in 10% neutral formalin. The fixed tissue were dehydrated and embedded in paraffin wax. Sections were cut at thickness of 6 $\mu$ m by rotary microtome and stained by Haematoxylin & Eosin and Periodic acid-Schiff (PAS) staining. Photographs of the slides were taken through Nikon Eclipse E200 microscope fitted with digital camera and analyzed by Nikon NIS Elements D imaging software.

## RESULTS

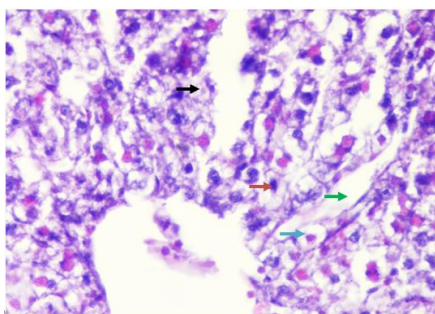
On examination of microscopic structure of the maternal liver of control mice (group I) normal liver architecture was observed. The hepatocytes were arranged in cords or plates radiating from the central vein. Sinusoids lining between the hepatic cords were lined with flattened endothelial cells and few Kupffer cells were also seen (Fig. 1). The cytoplasm of hepatic cells contained scattered basophilic granules with rounded nuclei. Proliferating binucleate hepatocytes were seen along with the normal hexagonal hepatocytes. The hepatic cells surrounding the portal triad were vacuolated with rounded nuclei. The PAS stained liver shows extensive intracellular glycogen granules in hepatocytes in hepatic as well as portal lobules (Fig. 5)

In group II marked distortion of typical hepatic laminar pattern was seen. The sinusoids were markedly dilated. The hepatocytes showed marked degeneration. Many of the cells were vacuolated and ruptured with exudation of the intracellular contents in the intercellular matrix. The nuclei were pyknotic and karyolysis and karyorrhexis. As a result there was considerable amount of cellular debris in the hepatic lobules (Fig. 2). In portal lobules, the cells were irregularly arranged around the portal triad. The nuclei around the triad showed marked karyolysis and karyorrhexis. The cells were vacuolated or ruptured giving spongiform appearance. The cellular debris was spread around the portal triad. At places the walls of the vacuolated cells were formed quite thickened indicating the non functional status of the cells. The walls of the degenerating cells with thickened in the hepatic lobules as well as portal lobules probably due to deposition of connective tissue. This may be act of eto cells. In the sinusoids the kupffer cells had increased in size and become rounded probably due to the phagocytic activity. All these activities indicated marked degeneration of hepatocytes (Fig. 2).

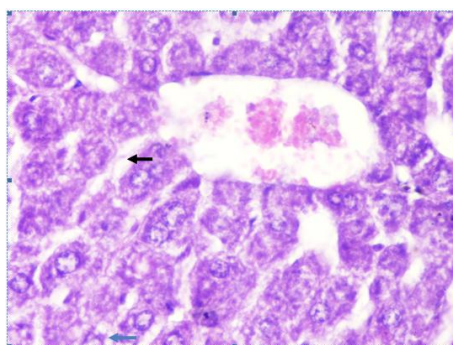
In group III, the laminar pattern of the hepatocytes was observed to be well preserved. The size of the hepatocytes was found to be increased in comparison to the hepatocytes of group I. In hepatic lobule dilatation of the sinusoids was seen. The vacuolation were present in the hepatic parenchyma(Fig. 3).



**Figure 1: Control liver showing hepatic cords and well developed sinusoids in hepatic lobule.H/Ex400**



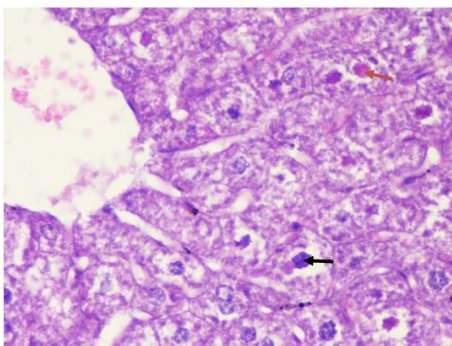
**Figure 2: Valproic acid treated liver showing dilated sinusoids (green arrow), degenerating hepatocytes (brown arrow), cell debris (black arrow), and vacuolated cells (blue arrow). H/Ex400**



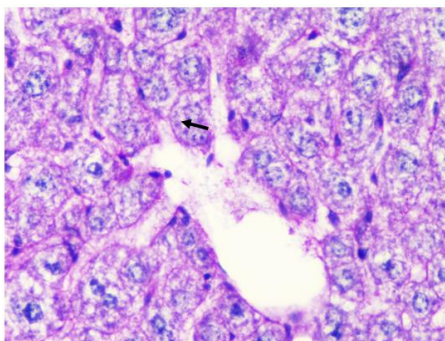
**Figure 3: Piracetam treated liver showing vacuolated hepatocytes (blue arrow) and dilated sinusoids (black arrow). H/Ex400**

In group IV, the laminar pattern of hepatocytes was preserved to certain extent. The nuclei in many of the cells showed karyolysis and karyorrhexis but it was less than in comparison those in group II. The cellular debris was infrequent as compared to group II. But in toto, the histological picture was comparable to the control group. It shows recovery of the cellular injury of induced by VPA in liver (Fig. 4).

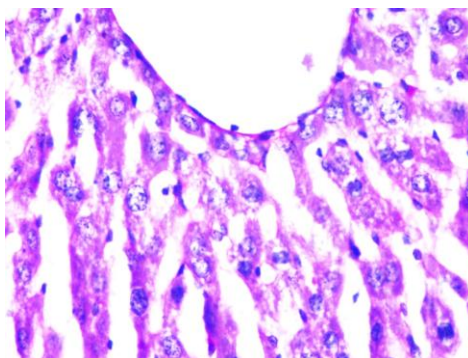
On PAS staining the hepatocytes in showed plenty of carbohydrates in form of glycogen granules in group I (Fig. 5). In group II, only a few glycogens in the hepatocytes immediately surround the central vein. The peripheral cells were deficient in glycogen granules (Fig. 6). In group III, there was presence of intracellular glycogen granules in hepatocytes but were less than in controls and more than in group IV (Fig. 7 and 8). In group IV, again plenty of PAS positive intracellular granules were observed. It was less than in controls but was much more than in group II (Fig. 5, 6 and 8).



**Figure 4: Valproic acid and Piracetam treated liver showing crumpled chromatin in hepatocyte (black arrow) and degenerating cells (brown arrow). H/Ex400**

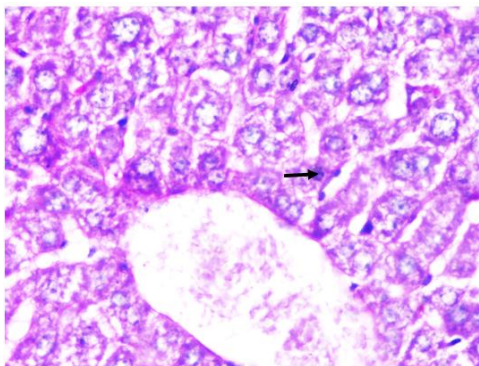


**Figure 5: Control liver showing intracytoplasmic PAS positive glycogen granules (Black arrow). PASx400**

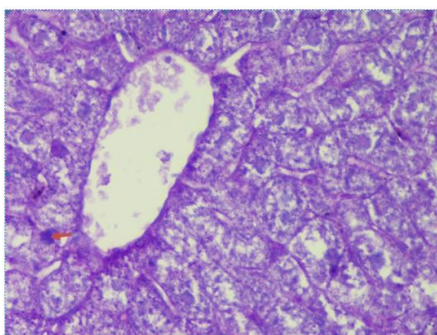


**Figure 6: Valproic acid treated liver showing negligible PAS positive granules. PASx400**





**Figure 7: Piracetam treated liver showing PAS positive granules (Black arrow). PASx400**



**Figure 8: Valproic acid and Piracetam treated liver showing restoration of PAS positive glycogen granules (Brown arrow). PASx400**

## DISCUSSION

Valproic acid caused partial to severe distortion of liver architecture, vacuolar changes in hepatocyte, inflammation in lobules of liver and patchy necrosis leading to spongiform appearance which was dependent on the severity of dosage. These finding corroborates with other studies who found similar effect on liver by valproate. These toxic effects were thought to be caused by impairment of fatty acid metabolism and derangement of urea cycle causing hyperammonemia which is a relevant marker of hepatic injury. Also the lipid peroxidation induced altered metabolites in Valproate treated mice may augment the liver injury[10,12-14].

However on the concurrent use of Piracetam with valproate, liver was salvaged to a considerable extent from the insult of valproate. The laminar pattern was preserved to a considerable extent and the degeneration of hepatocytes and the inflammatory exudates was substantially reduced. It also increased the glycogen granules in both the central and peripheral part of the hepatic lobules of the liver. This demonstrates that piracetam has substantial palliative effect from valproate induced liver injury. This could be explained on two grounds. First, the piracetam has an extensive cell membrane stabilizing action rendering it safe from cytopathological effects of valproate. Secondly, Piracetam also protects mitochondria from oxidative stress injury of valproate. Mitochondrion is a key element in ATP generation through

electron transport chain which helps to reduce the escalated apoptotic injury due to reduced energy generation.[22]

A study on rats found that piracetam improves both central and peripjeral microcirculation by reducing thrombocyte aggregation and erythrocyte deformity.[23] It is also able to prevent damage occurring after hemorrhagia in animals subjected to hypoxia by inducing hemorrhagic shock.[24] In an experiment piracetam was applied in order to observe its cytoprotective effect and anti-apoptosis influence by inducing hypoxia in the *in vitro* astrocyte cultures. Significant reduction in the number of cells exhibiting death or apoptosis was observed following piracetam treatment.[25] Piracetam is also able to inhibit free radical lipid peroxidation and slows down the oxygen consumption in liver mitochondria due to which it decreased the liver damage in the present study. It also accelerates aerobic and anaerobic glycolysis and increase ATP concentration.[26]

So, due to the cytoprotective, antihypoxic, antioxidant and microcirculation-improving effects, the piracetam could benefit the treatment of liver damage associated with valproic acid and it could be hypothesized that piracetam is a key agent in reducing the damages incurred by valproate on the liver and should be prescribed in unison with valproate.

#### REFERENCES

- [1] Villanueva-Gomez F, Fernandez-Miranda MC. Rev Neurol 2002; 35: 1–5.
- [2] Pedley TA, In: Goldman L, Bennett X, Cecil Text book of medicine, 21<sup>st</sup> edition. Philadelphia, W.B. Saunders co, 2000: pp. 2151-63.
- [3] Lowenstein DH, In: Braunwald E, Fauci AS, Kasper DL, et al. Harrison's Principles of Internal Medicine, 15<sup>th</sup> edition, USA: Mc Graw Hill, 2001: pp. 2354-69.
- [4] Scott WJ, Schreiner CM, Nau H, Vorhees CV, Beliles RP, Colvin J, McCandless D. Reprod Toxicol 1997 ; 11: 483-9.
- [5] Thurston JH, Hauhart RE, Schulz DW, Naccarato EF, Dodson WE, Carroll JE. Neurol 1981; 31: 1063-9.
- [6] Mortensen B, Gregersen N, Kolvraa S, Christensen E. Biochem Med 1980; 24: 153-61.
- [7] Turnbull DM, Bone Ad, Bartlett K, Koundakjian PP. Sherratt HAS. Biochem Pharmacol 1983; 32: 1887-92.
- [8] Coude FX, Grimber G, Pelet A, Benoit Y. Biochem Biophys Res Commun 1983; 115: 730-6.
- [9] Byorge SM, Baillie TA. Biochem Biophys Res Commun 1985; 132: 245-52.
- [10] Kesterton JW, Granneman GR., Machinist JM. Hepatol 1984; 4: 1143-52.
- [11] Kis B, Szupera Z, Mezei Z. Epilepsia 1999; 40: 307-310.
- [12] Siemes H, Nau H. Klin Padiatr 1991; 6: 411-419
- [13] Khan SK, Shakoora KA, Jan MA, Khattak AM, Shah SH. Gomal Journal Of Medical Sciences 2005; 3: 15-18.
- [14] Raza MA, Bekairi OA, Quershi SM. Int J Tissue React 2000; 22 (1): 15-21
- [15] Croisile B, Trillet M, Fondarai J, Laurent B, Manguiere F, Billardon M. Neurol 1993; 43: 301.



- [16] Waegemans T, Wilsher C R, Danniau A, Ferris S H, Kurz A, Winblad B. Demnet Geriatr Cogn Disord 2002; 13 : 217.
- [17] Winnicka K, Tomasiak M, Bielawska A. Acta Pol Pharma 2005; 62: 405.
- [18] Tortiglione A, Minale M, Pignataro G, Amoroso S, DiRenzo G, Annunziato L. Neuropharmacol 2002; 43: 427.
- [19] Stockmans F, Deberdt W, Nystrom A, Nystrom E, Stassen J M, Vermylen J, Deckmyn H. Thromb Haemost 1998; 79: 222.
- [20] Horvath B, Marton Z, Halmosi R, Alexy T, Szapary L, Vekasi J, Biro Z, Habon T, Kesmarky G, Toth K. Clin Neuropharmacol 2002; 25: 37.
- [21] Xerri C, Zennou-Azougui Y, Coq JO. ILAR J 2003; 44: 110.
- [22] Keil U, Scheroing I, Hauptmann S, Schuessel K, Eckert A, Muller WE, British J Pharmacol 2006;147:199-208
- [23] Stockmans F, Deberdt W, Nystrom A. Thromb Haemost 1998; 79: 222-227.
- [24] Grassler J, Wustmann C, Fischer HD, Schmidt J, Scheuch DW, Meth and Find Exptl Clin Pharmacol 1987; 9: 489-491.
- [25] Gabryel B, Adamek M, Pudelko A, Malecki A, Treciak HT. Neurotoxicol 2002; 23: 19-31.
- [26] Ertok E, Guven H, Erman M. The Medical J Akdeniz University 1995; 12: 1300-1309.