

Research Journal of Pharmaceutical, Biological and Chemical Sciences

A Cross-Sectional Study of Clinical and Histopathological Features of Vesiculobullous Skin Lesions.

Pavithra P^{1*}, Ragunatha S¹ and Sreelatha R²

¹Department of Pathology, Sri Siddhartha Medical College, Tumkur, Karnataka, India.

²Department of Pathology, Bangalore Medical College and Research Institute, Bangalore, Karnataka, India.

ABSTRACT

Vesiculobullous diseases are a group of disorders in which primary lesion is a vesicle or a bulla involving skin and/or mucous membrane. It is important to identify and diagnose these lesions correctly as some of them are fatal if untreated. Hence, the present study was conducted to demonstrate various types of vesiculobullous lesions (VBL) and their histopathological features. Over a period of 20 months 35 skin biopsies from patients with vesiculobullous skin lesions were sent to the Department of Pathology. In all these cases, punch biopsies measuring 4-5 mm were taken and stained with Haematoxylin and Eosin (H&E) and examined under a light microscope for level of blister, alterations in the morphology of keratinocytes, epidermal changes and characteristics of inflammatory infiltrate. During the study period, 170 skin biopsies were obtained out of which vesiculobullous lesional biopsies were 35 (20.59%) in number. Clinical and histopathological correlation was demonstrated in 14 (82.35%) cases of Pemphigus vulgaris (PV), 8 (88.88%) cases of Bullous pemphigoid (BP), 4 (100%) cases of Pemphigus foliaceus (PF) and one case of Hailey Hailey disease (HHD). Dermatitis herpetiformis (DH), bullous systemic lupus erythematosus (BSLE), subcorneal pustular dermatosis (SCPD) and friction blister were diagnosed based on histopathological features alone. Four cases showed inconclusive results. A high level of accuracy can be obtained by correlating the clinical and histological findings in the diagnosis of vesiculobullous disorders.

Key words: Vesiculobullous skin lesions; Punch biopsy, Pemphigus, Pemphigoid

**Corresponding author*

Email: drpavithra83@gmail.com

INTRODUCTION

Vesiculobullous diseases are a group of disorders in which primary lesion is a vesicle or a bulla, on the skin or mucous membrane or both. Among the various dermatological conditions, VBL form one of the most frequent clinical problems. Though some of them have a characteristic clinical presentation, many a times it may not be possible to make a definite diagnosis on cutaneous examination alone. So a histopathological examination is resorted to by many dermatologists for a definite diagnosis and classification.

Several factors need to be considered while studying histopathological features of VBL. These include, change in plane of separation and inflammatory infiltrate as blister ages; occurrence of only microscopic slit like spaces in clefting disorders like Darrier's disease; inability to assess specific mechanisms of blister formation accurately; and alteration in classical histological features caused by systemic or topical therapy [1].

Research techniques such as immunoblotting and immunoelectron microscopy may refine the diagnosis in the individual patient. However, these investigations are available only in advanced research laboratories. Even direct immunofluorescence (DIF) is done only in a few centres in developing countries like India [2]. Histological study is one of the most valuable means of diagnosis in Dermatology. The maximum diagnostic accuracy is obtained by correlating the clinical and histological findings [1].

MATERIALS AND METHODS

A cross sectional study was carried out in the Department of Pathology for a period of 20 months. Skin biopsies from the patients who were clinically diagnosed to have VBL were included for study. VBL due to congenital causes, infective conditions, burns and drug induced skin eruption were excluded from the study.

The biopsy was taken from early lesions. Under aseptic precaution and local anesthesia a punch biopsy measuring 4 mm to 5 mm was obtained. The specimen was collected in 10% buffered formalin. After fixation for 12-24 hours, the entire biopsy specimen was conventionally processed by a histokinette and embedded in paraffin. Serial sections of 3-5 micron thickness were taken and stained with haematoxylin and eosin (H&E). Detailed light microscopic examination was done. The separation plane of the blister, the mechanism of blister formation, alterations in morphology of keratinocytes and the character of the inflammatory infiltrate were observed.

RESULTS

A total of 170 (4.26%) skin biopsy specimens were received and VBL constituted 35 (20.59%) cases. There were 17 males and 18 females with a ratio of 1:1.05. PV was seen more commonly in males and BP in females with a ratio of 1.6:1 and 1:3 respectively. Majority

(54.28%) of the patients were in the age group 30-50 years. Table 1 shows clinical and histopathological diagnosis of VBL.

Table 1: Correlation between clinical and histopathological diagnosis

Sl. No	Diseases	Clinical diagnosis	Histopathological diagnosis
1	Pemphigus vulgaris	17	14
2	Bullous pemphigoid	9	8
3	Pemphigus Foliaceous	4	4
4	Hailey Hailey disease	1	1
5	Prurigo	2	SCPD, DH
6	Non healing ulcer	1	Friction blister
7	SLE	1	Bullous-SLE
	Total	35	31

Out of the 35 cases, 31 cases were clinically diagnosed as one of the varieties of VBL and remaining four were other than VBL. Of these 31 cases, 27 were confirmed on histology and remaining four cases were inconclusive. In 2 out of these latter 4 cases, the biopsy was inadequate as it included only the epidermis and in the other 2 cases, the upper portion of the epidermis was not seen. The four cases (other than VBL) which were diagnosed mainly on histopathology included the early lesions of BP, SCPD, DH and the friction blister.

The histopathological features of PV (fig 1) and BP (fig 2) are indicated in table 2 and 3 respectively. In PF (fig 3), subcorneal bulla was seen in all 4 cases and acantholysis in 3. Eosinophilic spongiosis was noted in one case. In SCPD (fig 4), a subcorneal bulla filled with mixed inflammatory infiltrate was seen. No acantholytic cells were seen. In DH (fig 5), dermal papillae with neutrophilic infiltrate at their tips were seen. In HDD (fig 6), there was a suprabasal bulla containing partially acantholytic cells giving the appearance of “dilapidated brick wall”. In BSLE (fig 7), microscopy showed a striking basal layer vacuolization and subepidermal blister formation. Neutrophilic infiltrate was seen in the upper dermis. Single case of friction blister was encountered. Patient had a non-healing ulcer over his right gluteal region. An edge biopsy from the ulcer showed an intraepidermal bulla adjacent to a site of pseudoepitheliomatous hyperplasia. The floor of the bulla was lined by intact basal layer of epidermis. A few degenerated keratinocytes were seen within the bulla. This was an incidental finding.

Table 2: Histopathological features in PV

S.No.	Histopathological features	No. of cases	Percentage
1	Suprabasal cleft/bullae	10	71.43
2	Mid epidermal vesicle/bullae	4	28.57
3	Acantholysis	12	85.71
4	Eosinophilic spongiosis	4	28.57
5	Row of tomb stone	4	28.57
6	Infiltrates in the bulla	2	14.28

Table 3: Histopathological features in Bullous pemphigoid

S.No.	Histopathological features	No. of cases	Percentage
1	Subepidermal bullae	8	100
2	Bullae with inflammatory cell rich infiltration	4	50
3	Bullae with inflammatory cell poor infiltration	4	50
4	Perivascular infiltration	5	62.5

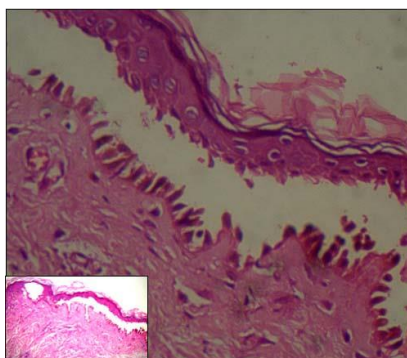


Figure1: Photomicrograph showing suprabasal bulla in pemphigus vulgaris (10x40X). Inset showing scanner view of the same (10x4X)

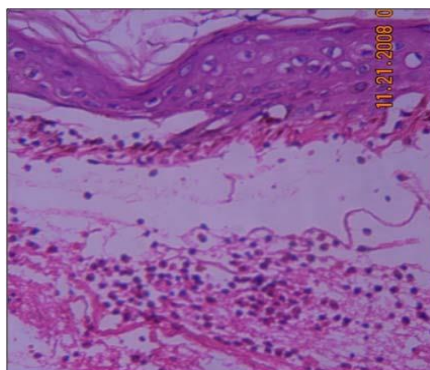


Figure 2: Subepidermal bulla containing eosinophils – seen in bullous pemphigoid (10x40X)

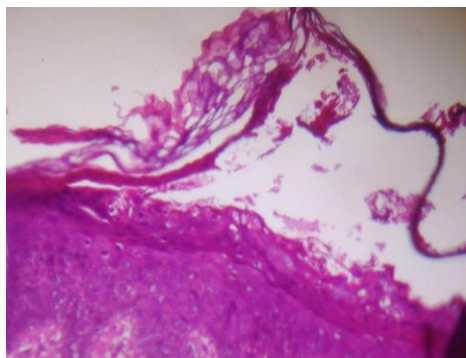


Figure 3: Subcorneal bulla in Pemphigus foliaceus (10x10X)

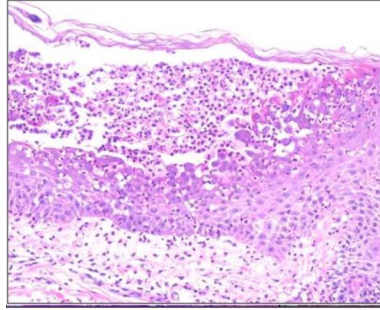


Figure 4: Subcorneal pustular dermatosis showing subcorneal pustule (10x10X)

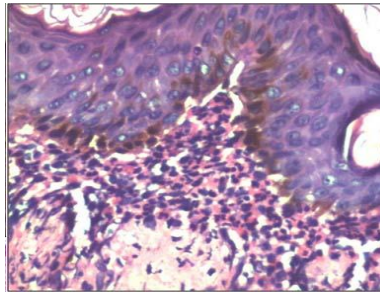


Figure 5: Neutrophilic microabscess seen in the papillary dermis in DH (10x40X)

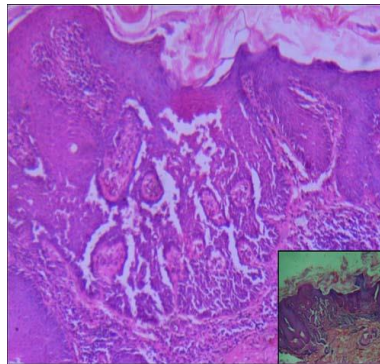


Figure 6: Photomicrograph of HHD showing suprabasal acantholysis (10x10X). Inset showing scanner view of the same (10x4X)

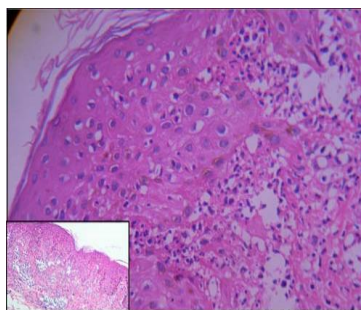


Figure 7: Subepidermal clefts and neutrophils in the papillary dermis – in bullous SLE (10x40X). Inset showing low power view of the same (10x10X)

DISCUSSION

VBL comprise a group of eruptions of different etiology and prognosis, but sharing a common characteristic, the formation of blister cavities within different layers of the epidermis or beneath the epidermis. Most of the basic types can be diagnosed by light microscopy. It is still one of the simplest and most consistent methods for diagnosis and classification of VBL.

The proportion of intraepidermal and subepidermal blistering disorders in the present study is comparable with other studies [3]. PV (40%) constituted the largest group in the present study. However, in other studies the proportion of PV cases range from 72[4] -83% [5]. Clinically, all the patients with vesiculobullous diseases may not present with classic morphology and distribution of the lesions. The number of patients presenting with clinical features like vesicles and bullae, involvement of mucous membranes, Nikolsky's sign and Bulla spread sign is different in various studies conducted in India. The difference may be due to prevalence of the diseases, severity and stage of the disease at presentation and status of the treatment. In these clinical scenarios where clinical diagnosis is difficult, histopathology of biopsy specimen will help in arriving at final diagnosis [2].

All the vesiculobullous diseases show specific histopathological changes which are demonstrated only when early intact vesicle or bulla is included in the biopsy specimen. Similar to clinical features, the number of specimens showing specific histopathological changes is different in various studies conducted in India. In PV, suprabasal bulla has been reported in 54.16% [6]- 94.4% [7], midepidermal cleft in 45.83% [6], acantholysis in 11.3% [7]-91.6% [6], spongiosis in 61.1% [7] and row of tombstones in 55.5% [6] of cases. Eosinophilic spongiosis, an earliest feature of PV, means epidermal spongiosis with exocytosis of eosinophils [8]. It is seen in 4 (28.57%) cases of PV in our study which is in comparison with study by Parischa JS where it was seen in 36.5% cases [9]. In spongiosis, desmosomal stretching occurs prior to cell separation, while in acantholysis, cell separation occurs without stretching [7]. In PF, subcorneal separation and acantholysis has been observed in 100% and 75% cases in our study while it is present in all cases in a study by Deval Vora et al [6]. In BP, subepidermal separation has been observed in 100% cases which are similar to the study by Nishioka K et.al [10]. These variations may be due to differences in site or type of lesion selected for biopsy. The histopathological changes noted in SCPD [11], HHD [12], DH [13, 14] and BSLE [15] were consistent with other studies. In some cases, the histopathological changes can be non-specific. This was probably because the biopsy taken from the bulla did not include the adjacent perilesional skin due to which the roof of the bulla was detached from the base.

Therefore it is important to include the epidermis, dermis and subcutaneous tissue below the lesion as well as the perilesional area, to prevent detachment of the roof of the blister from the base. If the histopathological study is non-confirmatory and clinical features strongly suggestive of one of the immunobullous disease, DIF study is recommended.

CONCLUSION

With a good clinical history and physical examination of the patient and light microscopic evaluation of the representative biopsy, it is possible to diagnose most of the cases. Analysis of the subtle light microscopic features apart from the classic diagnostic features will assist in the diagnosis of difficult cases.

REFERENCES

- [1] Hong WU, Brian S, Terence JH. Non-infectious vesiculobullous and vesiculopustular diseases. 9th ed. In: Levers Histopathology of the Skin, David EE, George FM, Rosaliets, Bennett LJ Jr, eds. India: Lippincott Williams and Wilkins; 2005. pp. 243-91.
- [2] Arundhati S, Ragnatha S, Mahadeva KC. JCDR 2013; 7(12): 2788-92.
- [3] Nanda A, Dvorak R, Khlood AS, Humocid AS, Alsaleh QA. Int J Dermatol 2004;43:876-81.
- [4] Md Nurul Amin, Maidul Islam AZM. Int J Dermatol 2006;45:1317-8.
- [5] Soner Uzun, Murat Durdu, Ayse Akman, Suhan Gunasti, Canan Uslular, Hamdi R Memisoglu, Erkan Alpsoy. Int J Dermatol 2006;45:523-8.
- [6] Deval Vora, Vijay P, Viral B, Dimple A M, Bharat B, Meet Kumar. Iranian J Dermatol 2010; 13, 2: 42-6.
- [7] Leena, Vijaya B, Manjunath GV, Sunila. J Clin Diag Res 2010; 4:2446-2451.
- [8] Edward Ruiz, Jau Shyong Deng, Edward A Abell. J American Acad Dermatol 1994; 30(6): 973-76.
- [9] Parischa JS. IJDVL 1988; 54(4): 196-98
- [10] Nishioka K, Hashimoto K, Katayama I, Sarashi C, Kubo T, Sano S. Arch Dermatol 1984; 120: 1166-68.
- [11] Mittal RR, Singla A, Gill SS. Indian J Dermatol Venerol Leprol 1993; 59:288-9.
- [12] Rao AG. Indian J Dermatol 2013;58:412
- [13] Fraser NG, Kerr NW, Donald D. British J Dermatol 1973; 89:439-49.
- [14] Nicolas ME, Krause PK, Gibson LE, Murray JA. Int J Dermatol 2003; 42:588-600.
- [15] Karen C Parviainen, Leshner JL. Bullous SLE. The Internet J Dermatol 2003; 2(1).