



Research Journal of Pharmaceutical, Biological and Chemical Sciences

Amelioration of Histopathological Effect of Lead Induced Testicular Damage by *Vernonia Amygdalina* Leaves

¹Ligha AE*, ²Kola-Ojo OB, and ²Jegede AE

¹Department of Anatomy, Faculty of Basic Medical Sciences, Niger Delta University Wilberforce Island, Bayelsa State

²Department of Anatomy, Faculty of Basic Medical Sciences, Ladoke Akintola University, Oshogbo, Osun State.

ABSTRACT

Vernonia amygdalina is a perennial herb belonging to the Asteraceae family. It is well known antioxidant that plays a major role in African ethnomedicine. A total of twenty one male wistar rats were used to study the attenuation of the histopathological effect of lead induced testicular damage. Twenty one rats were randomly distributed to the three groups. Group I served as control. Group II received 50mg/kg of lead acetate and group III received 50mg/kg of lead acetate and 50mg/kg of *Vernonia amygdalina* given together. The experiment lasted for twenty one days. Results revealed normal testicular architecture and sperm count, morphology and motility in the normal control. Group II showed alteration of germinal epithelium, distortion of seminiferous tubules as well as lack of proper spermatogenic series. There was also a significant reduction in sperm analysis parameters in this group. The effects of the extracts of *Vernonia amygdalina* on the rats' testes showed improvements compared to both the control and lead treated group in all parameters measured. We therefore, conclude that leave extract of *Vernonia amygdalina* prevented to a certain degree, the advert effects of lead acetate on the testicular tissue.

Keywords: antioxidant, alkaloids, testes, factors, taste

**Corresponding author*



INTRODUCTION

The use of herbal extract from plants found in their natural habitat for the treatment of various types of illnesses and diseases has increased over the years [1]. In the area of phytochemicals, interest has been focused on the anti-inflammatory and antioxidant properties of polyphenols found in various botanical agents [2]. In fact, fruits and plants are rich sources of phenolic compounds and have been recognized to possess a wide range of properties including antioxidant, antibacterial, anti-inflammatory, hepatoprotective and anticarcinogenic actions[3,4].

Vernonia is a genus of about 1000 species of forbs and shrubs in the family Asteraceae. Some species are known as Ironweed. The genus is named after English botanist William Vernon. Vernonia amygdalina (VA), commonly called bitter leaf, is a perennial shrub of 2-5 m in height that grows throughout tropical Africa. It belongs to the family Asteraceae, has a rough bark with dense black straits, and elliptic leaves that are about 6 mm in length. The leaves are green and have characteristic odor and bitter taste [5]. In many parts of West Africa, the plant has been domesticated[6]. It is known as 'Ewuro' in Yoruba, 'Etidot' in Ibibio, 'Onugbu' in Igbo, 'Itiyuna' in Tiv, 'Oriwo' in Edo, and 'Chusar-doki' in Hausa [7]. It is known as 'Kiriologbo' in Ijaw (Izon).

The aqueous extract is used as tonic drink used as anti-helminthiasis, as laxative, anti-malaria enema, expectorant, worm expeller, fertility inducer in subfertile women and trypanocide[8]. In Northern Nigeria, it has been added to horse feed to provide a strengthening or fattening tonic called 'Chusar Doki' in Hausa[9] The leaves have also been used in Ethiopia as hops in preparing tela beer [10] . The leaves are widely used for fevers and are known as a quinine–substitute in Nigeria and some other African countries [5,11]. Some wild chimpanzees in Tanzania had been observed to use this plant for the treatment of parasite related diseases [12]. It has been found that Vernonia amygdalina has an astringent taste, which affects its intake [13]. The bitter taste is due to anti-nutritional factors such as alkaloids, saponins, tannins and glycosides [14]. The organic fraction extracts of the plant was shown to possess cytotoxic effects towards human carcinoma cells of the nasopharynx[15]. It is effective against amoebic dysentery [16], gastrointestinal disorders [17], and has antimicrobial and antiparasitic activities [18,19], depicts the various traditional uses of Vernonia amygdalina. The biologically-active compounds of Vernonia amygdalina are saponins and alkaloids [20], terpenes, steroids, coumarins, flavonoids, phenolic acids, lignans, xanthenes and anthraquinone [21], edotides [22] and sesquiterpenes [15].

Although several studies have reported its antioxidant properties, to the best of our knowledge, there is no reference in literature to the possible protective effect on lead induced testicular damage. The present study was carried out to establish the probable protective effect of Vernonia amygdalina on lead induced testicular damage in wistar rats.



MATERIALS AND METHODS

Animals and Treatment

Twenty one adult male wistar rats were used for this study after ethical clearance. They were obtained from Animal House Academy, Iwo road, Ibadan, Oyo state. The rats were acclimatized for two weeks before the commencement of the work.

Drug Administration

Animals in the treatment group received lead acetate dissolved in distilled water at a dose of 50 mg/kg administered intra-peritoneally.

Collection and Preparation of Vernonia Amygdalina Leave Extract

Fresh but matured leaves of Vernonia amygdalina were purchased from a local market in Ogbomosho, Oyo state. They were authenticated by a Botanist in the Biological Sciences Department, Ladoko Akintola University of Technology, Ogbomosho, Oyo state, Nigeria. The leaves were rinsed severally with clean tap water to remove dust particles and debris and after allowed to drain completely.

Plants materials were separately chopped into bits with a knife on a chopping board. The leaves were then air dried and one kilogram (1kg) Vernonia amygdalina was reduced to powder with an electric blender. The powder was percolated with distilled water. The mixtures were kept for forty-eight (48) hours in the refrigerator at 4⁰C for thorough extraction of the plant's active components. These were then filtered with cheese cloth and later with whatman no 1 filter paper to obtain a homogenous filtrate. These filtrates were then concentrated in vacuum at low temperature (37-40⁰C) to about one tenth the original volumes using a rotary evaporator. The concentrates were allowed open in water bath (40⁰C) for complete dryness of the aqueous extracts of Vernonia amygdalina.

Experimental Design

Twenty one mature male wistar rats were used in this study and the rats were randomly distributed into three groups of seven rats per each group. The detail is as highlighted below:

Group I: This group served as the control and the rats were fed with pelletized Grower's Marsh and water was given ad libitum .

Group II: Animals in this group were administered with 50mg/kg of lead acetate for three weeks.

Group III: In this group, in addition to lead acetate administered at 50mg/kg, extract of Vernonia amygdalina was concurrently administered for three weeks.

The average weight for rats was 147.9g. The animals were housed in perforated plastic cages under hygienic conditions.

Retrieval of Tissues

At termination, the rats were anaesthetized with ketamine 1 mg/kg (intramuscularly). To remove the testis, a pair of scissors was inserted into the preputial orifice and cut through the ventral foreskin that covers the tip of the penis. Then penis was pulled caudally and the midventral abdominal muscles removed to expose the pubic symphysis. With the scissors, the pubic symphysis was carefully cut through and the hind legs pulled apart to expose the pelvic canal. On the surface of the testis is the epididymis a coiled tube identified. The testis removed by cutting the spermatic cord. Testes were then collected in buffered Buin's fluid after the procedure of sperm collection.

Tissue Preparation for Histology

The testes were dehydrated through ascending grades of alcohol (70%, 80%, 90%, absolute) for about 24 hours. The tissues were then cleared in xylene, infiltrated and embedded in paraffin wax. Sections of 5 micron thickness were cut on Reichert ultra microtome, mounted on slides and stained with Haematoxylin first then rinsed, followed by Eosin. The slides were dehydrated in ascending alcohol solution, cleared. A coverslip is mounted onto a labeled glass slide with Permount. Tissues prepared were examined for differences in comparison to the control group by an anatomical pathologist blinded to the nature of the experiment.

SEMEN ANALYSIS

Sperm count

The caudal part of epididymis was excised and transferred into 1 ml of normal saline for about 3 minutes for spermatozoa to swim out after which a drop of saline is transferred to the Neubauer counting chamber (haemocytometer) for semen analysis under the light microscope. Sperm count was done strictly according to the recommended protocol of the WHO manual [22]. Spermatozoa are viewed and counted under a light microscope, the haemocytometer is divided into nine fields, but spermatozoa are counted and recorded for just five random fields and the value is recorded in millions (10^6) [23].

Sperm morphology

The morphology of the sperms was evaluated to determine the various form and external feature of the sperm and is thus grouped into either normal or abnormal in accordance with WHO protocol [22].

Sperm motility

This parameter is taken to access and differentiate the sperm cells based on their movement. The classification is done via a more specified measure called the motility grade, where the motility of the sperm is divided into four grades. Each sample was assessed twice. For consistency, all readings were carried out at 37⁰C in accordance with WHO protocol [22].

- Grade a: (Sperm with progressive motility). These are the strongest and swim fast in a straight line. Sometimes it is also denoted motility I.
- Grade b: (non-linear motility): These also move forward but tend to travel in a curved or crooked motion. Sometimes also denoted motility II.
- Grade c: These have non-progressive motility because they do not move forward despite the fact that they move their tails. Sometimes also denoted motility III.
- Grade d: These are immotile and fail to move at all. Sometimes also denoted motility IV.

Statistical Analysis

The data obtained were evaluated by one way ANOVA by the use of GraphPad InStat version 3 software. All results were expressed as mean \pm S.E.M (standard error of mean) $P < 0.05$ was accepted as significant in this study.

RESULTS

Histopathological Observations

In both control and group III in which lead was concurrently administered with *Vernonia amygdalina* leave extract, there were numerous seminiferous tubules containing germ cells of various stages of maturation; spermatogonia, spermatocytes, spermatids and spermatozoa, arranged with a normal polarity with the spermatogonia closer to the basement membrane and spermatozoa towards the lumen of the seminiferous tubules. The Sertoli cells (sustentacular cells) in between the spermatogonia were also observed as illustrated in Fig.1 and 2. These findings were contrary to the group II which was treated with lead acetate, revealing germ cell disorganization, depletion of spermatogenic epithelium vacuolations, loss of loosely packed interstitial space, and interstitial fibrosis (fig.3).

Sperm Analysis

Result in lead treated group showed a significant reduction in sperm count, motility and morphology in comparison to the control group ($p < 0.05$). Concurrent administration of *Vernonia amygdalina* leaves and lead acetate enhances sperm analysis parameters to a reasonable degree as shown in fig.4, tables 1 and 2 respectively.

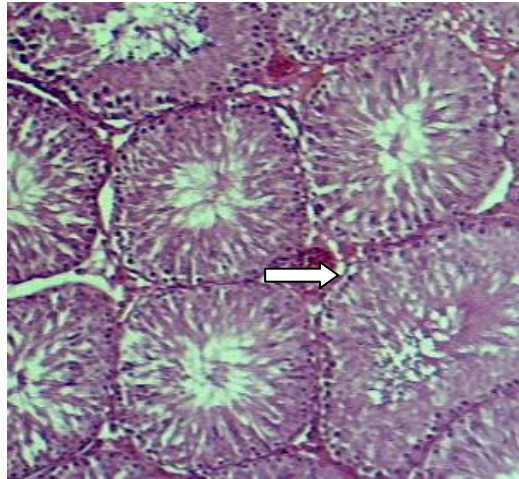


Fig.1. Shows a photomicrograph of the testes of the control group, H&E stain. The architecture of the testis shows the proper arrangement of the seminiferous tubules, spermatogenic series and prominent interstitial cells of Leydig (MAG.x40).

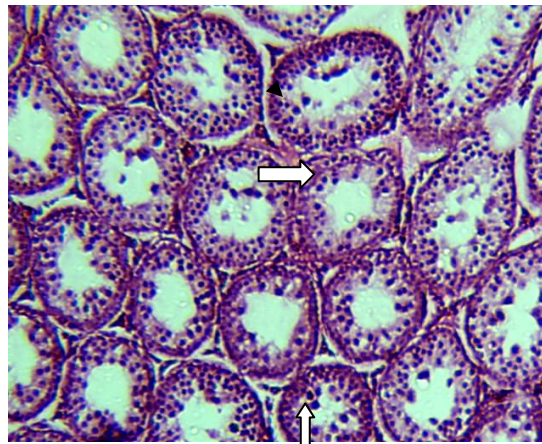


Fig.2. Shows the testes of group II treated with 50 mg/kg of lead acetate using H&E stain. The seminiferous tubules appear shrunken with distorted spermatogenic series and almost absent spermatozoa. Leydig cells are absent. There is also interstitial fibrosis. MAG.x40.

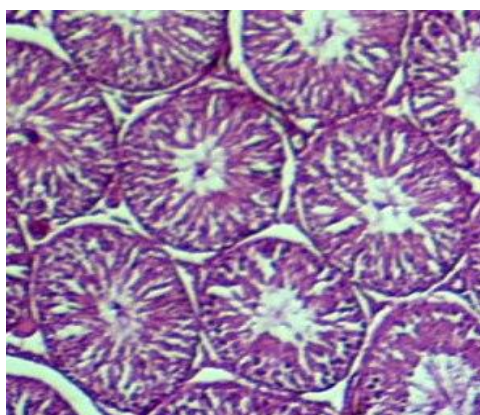


Fig.3. Shows testis of group III; concurrently administered with lead and Vernonia amygdalina. The photomicrograph shows near to normal architecture. (MAG.x40).

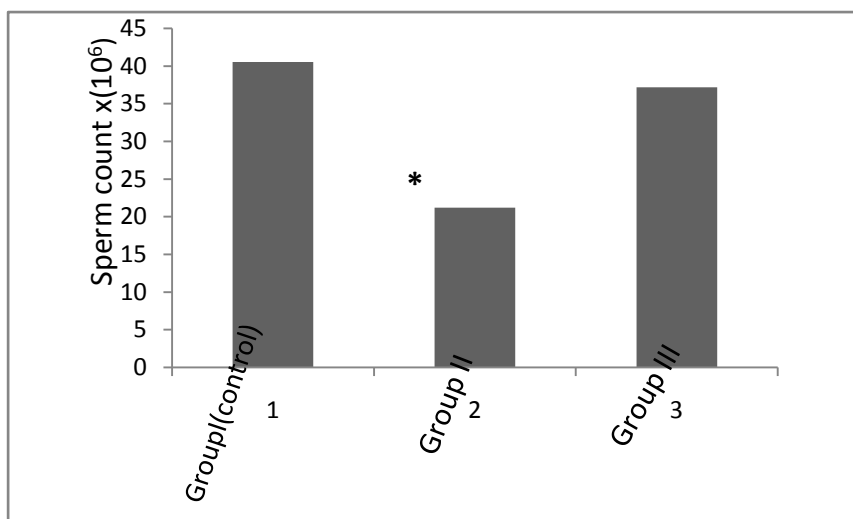


Fig.4. Sperm count of both control and treated rats. All values are expressed as Mean±SEM (n=7). Groups are as follows: Group I(control); no treatment, Group II; treated with 50mg/kg of lead acetate, Group III; treated with 50mg/kg of lead acetate and 50 mg/kg of Vernonia amygdalina simultaneously for three week. * =P<0.05 (statistically significant)

Table 1. Sperm Motility of Control and Treated Rats

Grade of movement	Group I (Control) n=7	Group II n=7	Group III n=7
RAPID PROGRESSIVE MOVEMENT	25.13 ± 0.80	12.08 ±1.30*	24.22 ± 1.36
SLOW PROGRESSIVE MOVEMENT	14.52 ± 0.57	15.12 ±1.21	22.56 ± 1.42*
NON PROGRESSIVE MOVEMENT	34.02 ± 0.49	40.31 ±2.54*	32.42 ± 2.61
DEAD SPERM CELLS	26.33 ± 0.54	32.49±1.21*	27.66 ± 1.84

All values are expressed as Mean±SEM (n=7). Groups are as follows: Group I(control); no treatment, Group II; treated with 50 mg/kg of lead acetate, Group III; treated with 50 mg/kg of lead acetate and 50 mg/kg of Vernonia amygdalina simultaneously for three week.

* =P<0.05(statistically significant)

Table 2. Sperm Morphology of Control and Treated Wistar Rats.

Morphology	Control group n=7	Group II n=7	Group III n=7
NORMAL SPERMATOZOA	30.33 ± 0.40	16.36±1.09*	34.54 ± 2.02
HEAD DEFECT	59.27± 1.04	62.15±2.02	55.26 ± 2.12*
MIDDLE PIECE DEFECT	5.24 ±07	15.09±2.91*	7.06 ± 0.03
TAIL DEFECT	5.16 ± 1.80	8.40±2.11*	3.14 ± 1.20

. All values are expressed as Mean±SEM (n=7). Groups are as follows: Group I(control); no treatment, Group II; treated with 50mg/kg of lead acetate, Group III; treated with 50mg/kg of lead acetate and 50mg/kg of Vernonia amygdalina simultaneously for three weeks.

* =P<0.05(statistically significant)

DISCUSSION

The findings of this study show that Lead (acetate) has a deleterious effect on the reproductive system, specifically the testes. This is consistent with the research carried out

by Garu et al. [24]. However, this damage was prevented by the administration of plant extract of *Vernonia amygdalina* commonly called bitter leaf. The histological observations of testicular sections of lead treated rats which show germ cell disorganization, depletion of spermatogenic epithelium, loss of loosely packed interstitial space and interstitial cell loss is in conformity with work done by Batra et al. [25]. These findings are not specific as there are known to be different responses of varying doses of lead induced oxidative stress in various target sites including the sperm[26].

Defective sperm function evidenced by the decrease in sperm count and other morphometric parameters in the lead treated group in this present study may have been caused majorly by free radical activities as being postulated by Sharma and Agarwal [27]. The detrimental Reactive Oxygen Species (ROS) effect on the sperm is said to be protected by the powerful antioxidants in seminal plasma and in its absence results to sperm dysfunction [28]. In light of the above, it is therefore, not surprising that testes of rats administered with *Vernonia amygdalina* showered improvement in the parameters measured. *Vernonia amygdalina* is a known powerful antioxidant with the ability to scavenge Reactive Oxygen Species. This is in support of our finding that VA does not have a deleterious effect on the morphometric parameters of the testes, but rather led, to the improvement of parameters of sperm analysis and histo-architecture. An improvement of testicular functions observed in our work after a combined administration of VA and lead acetate may suggest that the leave extract of this plant has antioxidant properties that probable mop up free radicals produced by lead. This is in conformity with work carried out by Igile et al. [6]. where certain phytochemicals of VA were isolated and their antioxidant properties were demonstrated. The antioxidant activity of *Vernonia amygdalina* has been attributed to the presence of flavonoids, as reported by Igile et al. [6]. Using spectroscopic techniques, the study had isolated and characterized the flavonoids occurring in *Vernonia amygdalina*. Three flavones were identified with chemical and spectroscopic techniques namely: luteolin, luteolin 7-O- β -glucuronoside, and luteolin 7-O- β -glucoside. Determination of the antioxidant activity of the three flavones had shown that luteolin showed greater activity than the other two. Since flavonoids are established as possessing antioxidant activity [29,30]. It can be speculated that the antioxidant properties of *Vernonia amygdalina* can be attributed to the presence of these flavonoids.

CONCLUSION

Lead has been confirmed to be a toxicant that has a deleterious effect on the testes in male rats. This effect was ameliorated by the administration of plant extract of *Vernonia amygdalina* which is known to have antioxidant properties. It improved morphometric and histo-architecture of the testes. However, further research work is required to be carried out on *Vernonia amygdalina* to expand the existing knowledge about its enhancement in testicular function and its antioxidant properties.

REFERENCES

- [1] Rates SM. *Toxicon* 2001;39; (5): 603-613.
- [2] Farombi EO, Owoeye O. Antioxidative and Chemopreventive Properties of *Vernonia amygdalina* and *Garcinia biflavonoid* 2011; 8(6): 2533-2555.

- [3] Iwalokun BA, Efedede BU, Alabi-Sofunde JA, Oduala T, Magbagbeola OA, Akinwande AI. *J Med Food* 2006; 9:524–530.
- [4] Ligha AE, Fawehenmi HB. *Port-Harcourt Medical Journal* 2009; 3(2): 180-190.
- [5] Singha SC. *Medicinal plants of Nigeria*. Apapa, Lagos, Nigeria: published by Nigerian national press; 1965.
- [6] Igile, GO, Olezek W, Jurzysata M, Burda S, Fafunso M, Fasanmade AA. *J Agri Food Chem(USA)* 1994;42 (11): 445 –2448.
- [7] CA, Ijeh II. *Nigerian Journal of Nutritional Sciences* 2010; 31(2):58-61.
- [8] Akinpelu DA. *Fitoterapia* 1999; 70: 232–234.
- [9] Dalziel JM. *The useful plants of West Tropical Africa*. Crown overseas agents for the Colonies; London, UK: 1937: 65.
- [10] Getahun A. *Some Common Medicinal and Poisonous Plants Used in Ethiopian Folk Medicine*. Faculty of Science, Addis Ababa University; Addis Ababa, Ethiopia 1976: 63.
- [11] Abosi AO, Raseroka BH. *Br J Biomed Sci* 2003; 60:89–91.
- [12] Ohigashi H, Jisaka M, Takagaki T, Nozaki H, Tada T, Huffman MA, Nishida T, Kaji M, Koshimizu K. *Agri Biol Chem* 1991; 55:1201–1203.
- [13] Bonsi MLK, Osuji PO, Tuah AK, Umunna, NN. *Agroforestry System* 1995a; 31(3): 229 – 241.
- [14] Buttler, GW, Bailey RW. *Indian J Nutr Dietet* 1978; 15 (5): 154- 158.
- [15] Kupchan SM, Hemmnigway RJ, Karim A, Werner D. *J Org Chem* 1969; 34:3908–3911.
- [16] Moundipa FP, Kamini G, Melanie F, Bilong FC, Bruchhaus I. *Afr J Tad Cam* 2000; 62: 113–121.
- [17] Akah PA, Ekekwe RK. *Fitoterapia* 1995; 66:352–355.
- [18] Hladik C, Krief S, Haxaire C. *J Ethnopharmacol* 2005; 101:1–5.
- [19] Muraina IA, Adaudi AO, Mamman M, Kazeem HM, Picard J, McGaw LJ, Eloff JN. *Pharm Biol* 2010; 48:1103–110.
- [20] Cimanga RK, Tona L, Mesia K, Musuamba CT, De Bruyne T, Apers S, Hernan N, Miert VS, Pieters L, Totte J, Vlietink AJ. *J Ethnopharmacol* 2004;93:27–32.
- [21] Izevbigie EB. *Exp Biol Med* 2003; 228:293–298.
- [22] World Health Organization. *WHO Laboratory Manual for the examination of human semen and semen cervical mucus interaction*, 4th edition, Press syndicate of the University of Cambridge, Cambridge 1999.
- [23] M Turner, J Powell G, Sakkas D. *Oxford J Human Reprod* 2001; 16: 121-124.
- [24] Garu U, Sharma R, Barber I. *International Journal of Pharmaceutical Sciences and Research* 2011; 2: 2403-2407.
- [25] Batra N, Nehru B, Bansal M.P. *Reprod Toxicol* 1998; 72: 535-540.
- [26] Hsu PC, Liu MY, Hsu CC, Chen LY, Leon Guo Y. *Toxicol* 1997; 122: (1-2): 133-143.
- [27] Sharma RK, Agarwal A. *Urology* 1996; 48: 835-850.
- [28] Raji Y, Olufadekemi T, Kunle A, Olaleye SBMA, Gbasegesin MA, Awobajo FO, et al. *J Bioll Sci* 2007; 7: 41-46.
- [29] Mathew J, Latha PG, George V. *J Trop Med Plants* 2004; 5:217–221.
- [30] Schuldt EZ, Favias MR, Ribeiro-do-Valle RM, Ckless K. *Phytomed* 2004; 11: 523–529.