

Research Journal of Pharmaceutical, Biological and Chemical Sciences

Testicular Effects of Artemisinin: Are They Reversible?

Jonah Sydney Aprioku*

Department of Pharmacology, Faculty of Basic Medical Sciences, University of Port Harcourt, Port Harcourt, Nigeria.

ABSTRACT

Recent studies on artemisinins have shown that the potent antimalaria agents alter reproductive function in animal models. This work aims to investigate the reversibility or otherwise of their active metabolite, dihydroartemisinin (DHA)-induced testicular effects in guinea pigs. Different animal groups were orally administered standard and double therapeutic dose equivalents of DHA, and sacrificed after drug administrations. Other groups of animals were treated similarly and allowed to recover for 7 days before they were sacrificed, and a control group was given vehicle. Epididymal sperm analysis revealed significant ($p < 0.05$) and dose-dependent reductions in sperm count (42.1 %), motility (49.6 %), and viability (28.6 %), while abnormal sperm morphology was significantly increased by 139.8 % in DHA-treated (non recovery) animal groups, compared to controls. DHA also caused alterations in seminiferous epithelium and distortions in testicular architecture, with vacuolization, poor sperm cell differentiation and depressed spermatogenesis. In the contrary, there was no significant ($p > 0.05$) difference between sperm counts in recovery groups and controls. Similarly, there were no histopathological changes in the recovery groups, compared to control groups. The results indicate that DHA may cause direct deleterious effect on seminiferous tubules which may be reversible.

Keywords: Artemisinins, dihydroartemisinin, reversibility, spermatogenesis, vacuolization.

**Corresponding Author*



INTRODUCTION

Malaria has remained one of the leading causes of morbidity and mortality in most developing countries, especially in the sub-Saharan region where the disease is endemic [1]. Resistance of malaria to most available antimalarial drugs has continued to increase tremendously [2, 3], making treatment of the disease more difficult and necessitating the need for new effective drugs.

Artemisinin and its derivatives (artesunate, artemether, dihydroartemisinin, arteether and artelinic acid) are currently the most potent and effective antiplasmodial agents [4]. Artemisinin or Qinghaosu, as it is called in China, is the active compound isolated from the leaves of the Chinese shrub, *Artemisia annua*, which has been shown to be very potent against the plasmodium parasite. Currently, artemisinins are combined with other antimalaria drugs as artemisinin-based combination therapies (ACTs) to improve their efficacies and reduce the development of resistance to artemisinin drugs. The ACTs, which include artesunate-amodiaquine, artesunate-sulfadoxine-pyrimethamine, artemether-lumefantrine, artesunate-mefloquine and dihydroartemisinin-piperaquine, are currently the recommended first line agents for the treatment of uncomplicated malaria [5, 6]. Artemisinins have generally been considered to be well tolerated and safe [5]. However, recent studies have reported that they may affect reproductive function in the male [7-9], and the female [10]. All artemisinin compounds are metabolized to an active metabolite, dihydroartemisinin [4], which is also available as a drug. Dihydroartemisinin (also called dihydroqinghaosu or arteminol) is used in the clinical treatment of patients with falciparum malaria in many tropical countries and especially in the Asian countries. Like other artemisinin compounds, dihydroartemisinin (DHA) has been shown in earlier studies to adversely affect male reproductive function, causing direct deleterious effects on the seminiferous epithelium without disruption of the hypothalomo-pituitary axis in the testes [11,12]. DHA has been shown to cause more testicular adverse effects compared to other artemisinin derivatives and has been thought to be responsible for most of the testicular effects of artemisinin compounds [9].

This work is aimed at investigating the reversibility of artemisinins-induced testicular responses. The investigations were done with dihydroartemisinin, being the common metabolite of all artemisinins, in the guinea pig. The guinea pig animal model appears to be more suitable than most other rodents, because it has a closer homology to humans in terms of drug metabolism compared to other rodents [13,14], and also has a similar reproductive physiology as humans [15].

MATERIALS AND METHODS

Drug

Dihydroartemisinin- Alaxin^R (Bliss DVS Pharma. Ltd, Mumbai, India) was obtained from the Department of Pharmacy, University of Port Harcourt Teaching Hospital, Port Harcourt,

Nigeria. The drug was powdered in a glass mortar, mixed with distilled water and administered as aqueous suspension with a 1.0 mL syringe by oral gavage at 0.9 mL/kg body weight. The drug suspension was continuously agitated during administration in order to deliver the drug homogeneously to the animals.

Animals

Thirty outbred strains of adult male guinea pigs (*Cavia porcellus*) weighing between 650-670 g and aged 20-21 weeks were obtained from the animal house of the University of Port Harcourt. The animals were maintained under natural conditions (light- 12:12 hour light:dark cycle, at a temperature of $28.0\pm 3.0^{\circ}\text{C}$ and relative humidity at $50\pm 5\%$). They had free access to standard rodent chow (Topfeeds Ltd, Sapele, Nigeria) and tap water was given *ad libitum* during the entire period of study. They were housed in solid-bottom shoebox cages with wire bar lids and bedding was provided to allow absorption of urine. The animals were handled in accordance with the recommended guidelines for Care and Use of Laboratory Animals as promulgated by the Canadian Council of Animal Care [16].

Methods

The animals were divided into 5 groups (n=6), and orally administered standard therapeutic and double therapeutic dose equivalents of dihydroartemisinin (DHA), and vehicle. Group I received 2.2 mg/kg on first day, then 1.1 mg/kg daily for 6 days (total of 8.8 mg/kg), corresponding to the standard therapeutic dose and duration of administration of DHA for the treatment of uncomplicated malaria in humans [17]. Group II received 4.4 mg/kg on first day, then 2.2 mg/kg daily for 6 days (total of 17.6 mg/kg). Group I and II animals were sacrificed at the end of drug treatments on the 8th day, and these experiments were used to study dose-related effects of DHA on the testis. Group III animals were given the same treatment as group I and were allowed to recover in 7 days before being sacrificed. Group IV animals were given the same treatment as group II and were allowed to recover in 7 days before being sacrificed. Group III and IV experiments were used to study reversibility of DHA-induced effects on the testis. Group V, the control group was given distilled water (0.9 mL/kg) daily for 7 days, and sacrificed at the end of treatment. Animals were sacrificed by cervical dislocation under diethylether (BDH Chemicals Limited, Poole, England) anesthesia. They were then quickly dissected, the testes were excised and epididymal sperm was collected for analysis. The second testis of each animal was fixed in 10 % buffered formalin (BDH Chemicals Limited, Poole, England), routinely processed and examined for histopathological changes.

Sperm analysis

The caudal epididymis was carefully isolated and placed in a Petri dish containing 3.0 mL of NaHCO_3 buffered Tyrodes's Lactate solution (BDH Chemicals Limited, Poole, England). Several incisions (1.0 mm) were made on it and sperm was gently drawn into a plastic transfer pipette and transferred into 5.0 mL test tubes and was then vigorously shaken for homogeneity and dispersal of sperm cells. Sperm was then analyzed to determine sperm motility, sperm

count, percentage of viable sperm cells (sperm viability) and percentage of abnormal sperm cells (abnormal sperm morphology) using standard procedures [18]. Smears were prepared on histological slides and observed in a phase-contrast microscope at 400x magnification within 2 hours of sperm collection to analyze sperm motility. Sperm count was performed with the improved Neubauer counting chamber (hemocytometer). Smears were dried and observed in a phase-contrast microscope at 400x magnification to analyze sperm morphology. Sperm viability was done using the eosin/nigrosin stain.

Histopathological analysis

The testicular tissues were embedded in paraffin and tissue sections (5 μ m) were stained with hematoxylin and eosin, H&E (Bemac Scientific and Chemical Corporation, Lagos, Nigeria), and examined with light microscope- Nikon Eclipse E400 (Nikon Instruments Inc, NY, USA). All alterations from the normal structure were registered and histopathological changes between control and experimental animals were noted. The images were photographed with an Olympus Model BX51 microscope (Olympus Optical Corporation Limited, Tokyo, Japan) at magnification of 400x.

STATISTICAL ANALYSIS

Data were expressed as mean \pm standard errors of mean (n=6). The data were analyzed by one-way analysis of variance (ANOVA), followed by Dunnett's multiple comparison test using GraphPad Prism 5 Software. Differences yielding P-values <0.05 were considered statistically significant.

RESULTS AND DISCUSSION

There was significant and dose-dependent increase in mean epididymal sperm count (p=0.0326,p=0.0202), motility (p=0.0370,p=0.0230), and viability (p=0.0406,p=0.0401), while abnormal sperm morphology was increased (p=0.0603,p=0.0440) in DHA (1.1-2.2 mg/kg)-treated animal groups that were sacrificed immediately after drug administration (i.e., Groups I & II), compared to control group, i.e. Group V (Figure 1A). The DHA-induced values represented 34.9 and 42.1 % reductions in sperm count; 28.3 and 49.6 % reductions in sperm motility; and 18.9 and 28.6 % reductions in sperm viability, respectively, compared to the controls. In addition, abnormal sperm morphology values obtained in Groups I & II were higher, compared to control- Group V, though, only 2.2 mg/kg DHA produced significant (p<0.05) effect, which corresponded to 139.8 % increase, compared to control (Figure 1D). Furthermore, histopathological analysis of testes in Group I animals revealed mild vacuolization of seminiferous tubular cells, and reduced sperm production (Figure 3B); and Group II animals showed pronounced vacuolization of seminiferous tubular cells, poor differentiation of spermatogenic cells, moderate maturation rest and depressed spermatogenesis (Figure 3C), compared to normal testis in control group- Group V (Figure 3A).

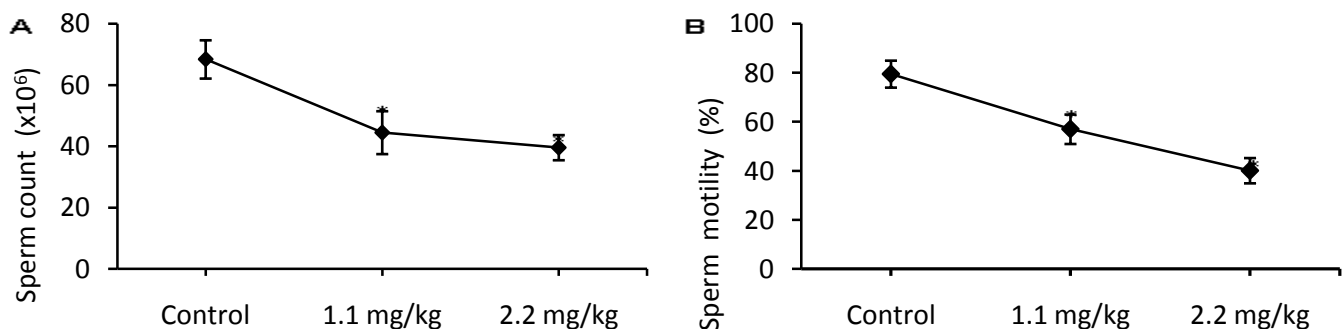
Artemisinin and its derivatives are highly efficacious drugs and very useful in the treatment of uncomplicated and resistant falciparum malaria [5,6]. In the recent past, these drugs have been of high interest in pharmacological research because of their wide and frequent usage, especially in the sub Saharan and other malaria endemic regions. Although, artemisinins have

been reported to be relatively safe, there has been recent concerns of their antireproductive effects in the male [8,9,12]. The testis, which is the main male reproductive organ, is primarily responsible for testosterone production and spermatogenesis, which occurs in the seminiferous tubules [19]. In addition, testicular cell function has been shown to be highly sensitive and compromised by a wide range of compounds [20-22], including antimalarials [23-25]. Thus, the toxicological profile of artemisinins on reproductive function remains an important concern.

Generally, studies on reproductive toxicity involve routine analysis of specific parameters including, sperm analysis and histopathological assessment of the testis [18,26]. Sperm count, motility, and viability are critical indicators of sperm quality and fecundity in the male [27]. In the present study, reductions in sperm count, motility, and viability by DHA treatment (Groups I & II) suggest strongly that DHA may affect testicular function, which is consistent with previous results [12]. In addition, the significant increase in percentage of abnormal sperm cells by DHA further reveals that the artemisinin metabolite adversely affects testicular function and may cause infertility. This is also consistent with previous findings [9,25]. Abnormal spermatozoa generally have lower fertilizing potential [28], and a large proportion of abnormal sperm cells can affect proper functioning of sperm and result in infertility [29]. Furthermore, the histopathological effects of DHA were positively correlated to its effects on sperm parameters. These results indicate that the DHA-induced alterations in sperm parameters may be due to direct deleterious effects on the seminiferous tubules, which are primarily involved in the process of spermatogenesis [19].

In contrast to the results obtained in the non recovery groups (Groups I & II), there was no significant ($p>0.05$) difference between sperm parameters (count, motility, viability and morphology) of recovery groups (Groups III & IV) and control- Group V (Figures 2A, 2B, 2C and 2D). Additionally, there were no histopathological changes in testes of Groups III & IV animals, compared to normal testis in the control group- Group V (Figures 3A, 3D and 3E). This indicates that there was a reversal of the DHA-induced adverse testicular effects in the guinea pig.

In a previous study, DHA has been shown to cause the highest level of testicular toxicity among other artemisinin derivatives, while artemether causes the least [9]. Also, the level of adverse testicular effects of artemisinin derivatives is considered to be dependent on the rate and extent of metabolism to the active metabolite [9]. Thus, the results of the present study with DHA, may represent reversibility of the testicular adverse effects of artemisinins.



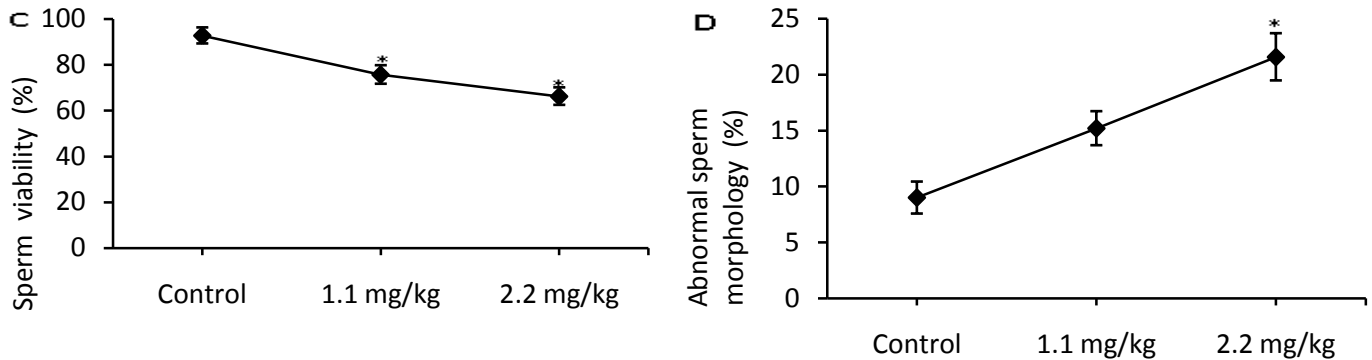


FIGURE 1: Effects on (A) sperm count, (B) sperm motility, (C) percentage of viable sperm cells (sperm viability), and (D) percentage of abnormal sperm cells (sperm morphology) following 7 day oral administration of dihydroartemisinin at daily doses of 1.1 and 2.2 mg/kg in guinea pigs
Data are expressed as mean \pm SEM, (n=6). * Indicates significant values at $p < 0.05$.
Animals were given double of the daily dose (i.e., 2.2 and 4.4 mg/kg, respectively) on first day of administration.

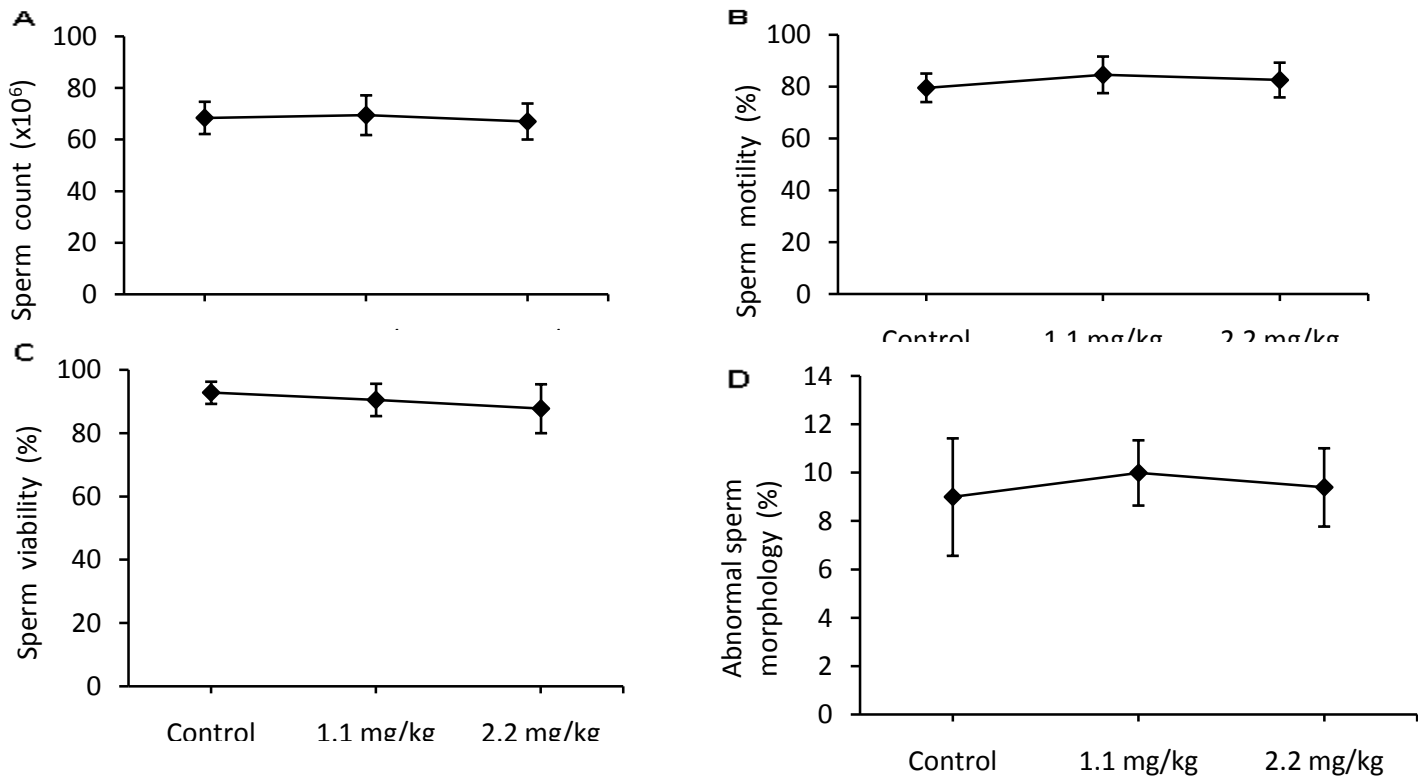


FIGURE 2: Effects on (A) sperm count, (B) sperm motility, (C) percentage of viable sperm cells (sperm viability), and (D) percentage of abnormal sperm cells (sperm morphology) following 7 day oral administration of dihydroartemisinin at daily doses of 1.1 and 2.2 mg/kg and subsequent withdrawal of drug for 7 days (reversibility of DHA-induced effects) in guinea pigs
Data are expressed as mean \pm SEM, (n=6).
Animals were given double of the daily dose (i.e., 2.2 and 4.4 mg/kg, respectively) on first day of administration.

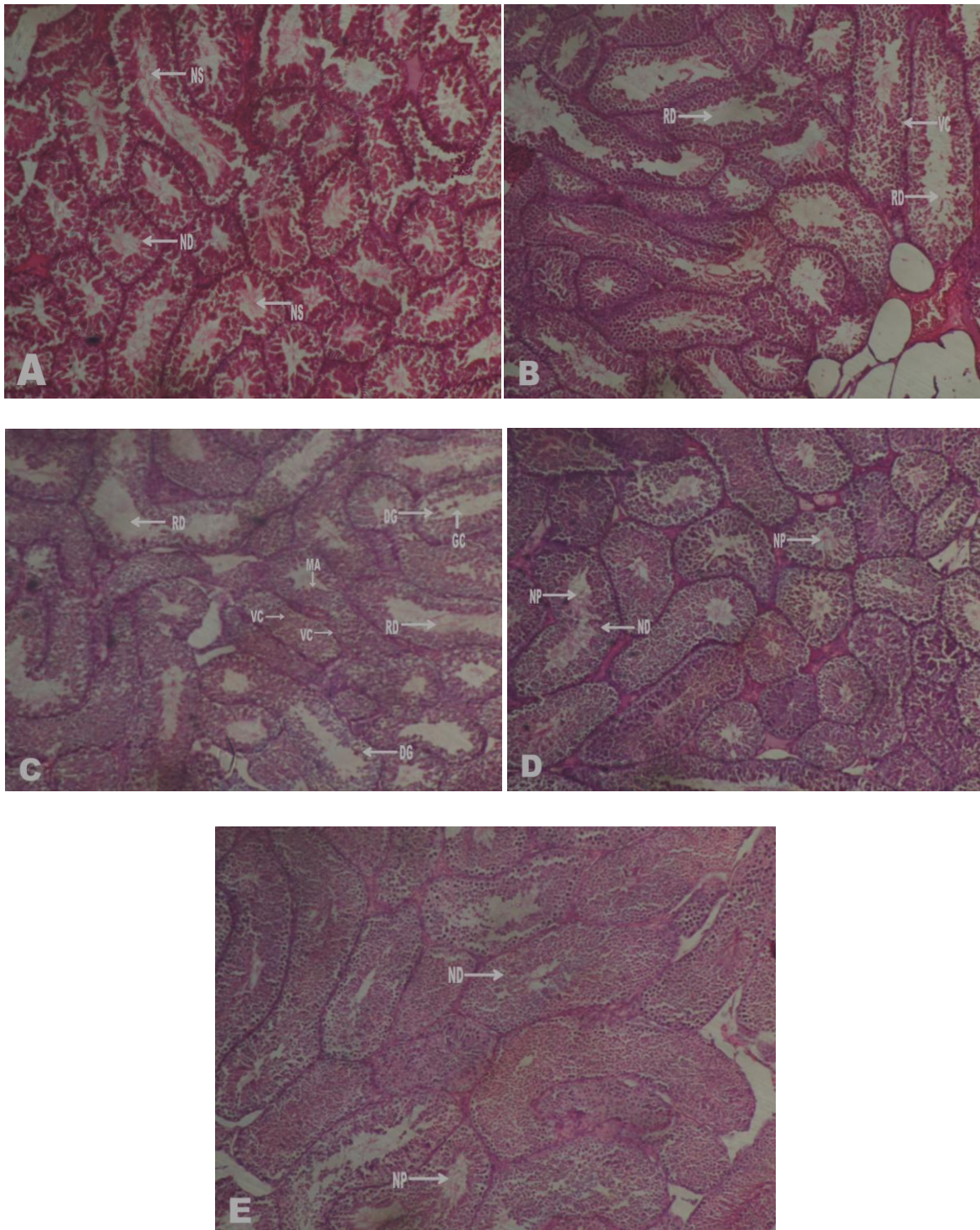


FIGURE 3: Photomicrographs showing effects on histology of testis following 7 day oral administration of dihydroartemisinin (1.1, 2.2 mg/kg) in guinea pigs (100x).

(A) *Group V (Control)*, showing normal histology of testis with normal seminiferous epithelium, normal spermatogenic cell differentiation (ND), and numerous spermatozoa in the lumen (NP). (B) *Group I (1.1 mg/kg)*, showing vacuolization of spermatogonia (VC), and reduced number of spermatozoa (RD). (C) *Group II (2.2 mg/kg)*,

showing disorientation and poor differentiation spermatogenic cells (DG), vacuolization of spermatogenic cells at different stages of development (VC), presence of giant spermatogenic cell in the lumen (GC), Arrest of spermatogenesis at the stage of spermatids (MA). (D) *Group III (1.1 mg/kg and withdrawn for 7 days)*, showing normal architecture of testis with normal spermatogenic cell differentiation (ND), and normal sperm production (NP). (E) *Group IV (2.2 mg/kg and withdrawn for 7 days)*, showing normal architecture of testis with normal spermatogenic cell differentiation (ND), and normal sperm production (NP).

Animals were given double of the daily dose (i.e., 2.2 and 4.4 mg/kg, respectively) on first day of administration.

CONCLUSION

Artemisinins alter testicular function which may be reversible over short term administration in the guinea pig. However, with the frequent use of these drugs, especially in malaria endemic regions, and their possible abuse, there may be need for further investigation of their reversibility following longer periods of administration.

ACKNOWLEDGEMENTS

The author thanks the technical staff of the Department of Pharmacology, University of Port Harcourt for their technical assistance.

REFERENCES

- [1] World Health Organization. World Malaria Report. In: World Health Organization; 2009, pp. 6-12.
- [2] Wongsrichanalai C, Pickard AL, Wernsdorfer WH, Meshnick SR. *Lancet Infect Dis* 2002; 2: 209-218.
- [3] Sharma V. *Mini Rev Med Chem* 2005; 5(4): 337-351.
- [4] Krishna S, Bustamante L, Haynes RK, Staines HM. *Trends in Pharmacological Sciences* 2008; 29: 520-527.
- [5] Nosten F, White NJ. *Am J Trop Med Hyg* 2007; 77(6): 181-192.
- [6] World Health Organization. Guidelines for the treatment of malaria. In WHO; 2nd ed. Geneva; 2010, pp. 5-18.
- [7] Obianime AW, Aprioku JS. *Nig J Physiol Sci* 2009; 24(1): 1-6.
- [8] Izunya AM, Nwaopara AO, Aigbiremolen AE, Odike MAC, Oiakghena GA, et al. *J Biol Med* 2010; 2(2): 49-56.
- [9] Aprioku JS, Obianime AW. *Insight Pharm Sci* 2011; 1(1): 1-10.
- [10] Rath B, Jena J, Samal S, Rath S. *Indian J Pharmacol* 2010; 42(3): 192-193.
- [11] Nwanjo HU, Iroagba II, Natuanya IN, Eze NA. *Internet J Endocrinol* 2007; 4: 1-5.
- [12] Obianime AW, Aprioku JS. *J Pharm Pharmacol Res* 2010; 1(1): 1-8
- [13] Hasan L, Vögeli P, Stoll P, Kramer SS, Stranzinger G, et al. *Mamm Genome* 2004; 15(4): 323-333.
- [14] Fernandez ML, Volek JS. *Nutr Metab* 2006; 3:17.
- [15] Harkness JE, Wagner JE. 3rd ed. Philadelphia: Lea and Febiger; 1989.
- [16] Canadian Council On Animal Care. Ottawa; 2009, pp. 12-15.

- [17] Looareesuwan S, Wilairatana P, Vanijanonta S, Pitisuttithum P, Viravan C, Kraisintu K. *Ann Trop Med Parasitol* 1996; 90: 21-8.
- [18] Seed J, Chapi RE, Clegg ED, Dostal LA, Foote RE, Hurtt ME, Klinefelter GR, Makris SL, Perreault SD, Schrader S, Seyler D, Sprando R, Treinen KA, Veeramachaneni DN, Wise LD. *Reprod Toxicol* 1996; 10: 237-244.
- [19] Clermont Y. *Physiol Rev* 1972; 52(1): 198-236.
- [20] Mostafa TG, Roaia MMF, Amer MK, Kader RA, Aziz A. *Andrologia* 2006; 38: 221-224.
- [21] McClusky LM, de Jager C, Bornman MS. *Toxicol Sci* 2007; 95: 249-256.
- [22] Afify M, Abd Elmaksoud MDE, Mosa T, Elshaer M, Kotb N. *New York: Science Journal*; 2010, pp. 10-18.
- [23] Osinubi AA, Ajala MO, Noronha CC, Okanlawon AO. *Afr J Med Med Sci* 2006; 35: 425-430.
- [24] Sadeghipour H, Vosooghi M, Sattarian M, Zahmatkesh M, Noori M. *Reprod Sci* 2010; 17(8): 748-753.
- [25] Obianime AW, Aprioku JS. *Int J Pharmacol* 2011; 7(1): 84-95.
- [26] Eliasson R. Basic semen analysis. In: Matson, P. (ed). *Current Topics in Andrology*. Perth, WA: Ladybrook Publishing; 2003, pp. 35–89.
- [27] Zinaman MJ, Brown CC, Selevan SG, Clegg EDJ *Androl* 2000; 21: 145-153.
- [28] Gandini L, Lombardo F, Paoli D, Caponecchia L, Familiari G, Verlengia C, Dondero F, Lenzi A. *Hum Reprod* 2000; 15: 830-839.
- [29] Menkveld R, Holleboom CAG, Rhemrev JPT. *Asian J Androl* 2011; 13: 59-68.