

Research Journal of Pharmaceutical, Biological and Chemical Sciences

Silymarin, protects against 7,12dimethyl-benz[*a*] anthracene -induced hepatotoxicity in albino rats

Mohamed SA. El-Gerbed

Doctor of Cell biology & Histology, Department of Zoology, Faculty of Science, Damanhour University, Damanhour, Egypt.

ABSTRACT

Exposure to environmental pollutants such as polycyclic aromatic hydrocarbon (PAH) is associated with the development of numerous cancers in human. Silymarin (SMN), a flavonolignans from milk thistle (*Silybum marianum*) plant, is used for the protection against various liver conditions in both clinical settings and experimental models. The present study has been carried out to investigate the protective role of silymarin against DMBA-induced hepatotoxicity in rats. Four groups of male rats were used, group I served as control, the animals of group II received silymarin only, group III were administered with DMBA and group IV received silymarin + DMBA. Evaluations were made for enzyme activities. Histopathological examination of liver was carried out by light and transmission electron microscopy. DMBA challenge elevated serum enzyme activities of liver and some biochemical parameters, but these effects were prevented by the treatment of rats with Silymarin. Histopathological examination under light and transmission electron microscope suggested a combination of necrosis and apoptosis. Changes such as cellular damage and mitochondrial degeneration, and/or condensation of nuclear chromatin were observed. Treating animals with silymarin improved the histopathological and ultrastructural alterations induced by DMBA. These results suggest that Silymarin exhibits potent hepatoprotective effects on DMBA -induced liver damage in rats.

Keywords: Silymarin, DMBA, Rats, Hepatotoxicity .

**Corresponding author*

INTRODUCTION

Intuition says the history of cancer has to be as old as the history of man himself. Egypt is also credited with one of the oldest description of cancer (1600 B.C.). Polycyclic aromatic hydrocarbons (PAHs) are organic pollutants that are released into the environment in large quantities mainly due to human activities [1]. Exposure to environmental pollutants such as polycyclic aromatic hydrocarbon (PAH) is associated with the development of numerous cancers in human [2] Environmental toxin 7, 12-dimethylbenz (a) anthracene (DMBA) is a member of PAH chemical group [3]. 7, 12- Dimethyl-benz[a] anthracene is a cytotoxic and carcinogenic [4], mutagenic [5] and immunosuppressive [6]. Experimental studies showed that DMBA can induce tumor [7].

Enzymatic activation of PAHs leads to the generation of active oxygen species such as peroxides and superoxide anion radicals, which induce oxidative stress in the form of lipid peroxidation. The PAH 7,12dimethyl-benz[a] anthracene (DMBA) acts as a potent carcinogen by generating various reactive metabolic intermediates leading to oxidative stress [8]. Epidemiological findings has provided evidence supporting the role of reactive oxygen species (ROS) such as singlet oxygen ($1O^2$), superoxide anions ($O_2^{\bullet-}$), hydrogen peroxide (H_2O_2), and hydroxyl radical ($\bullet OH$) in the etiology of cancer [9]. Certain aldehyde such as malondialdehyde(MDA), the end product of lipid peroxidation(LPO) arising from the free radical generation leading to the degradation of polyunsaturated fatty acids can cause cross-linking in lipids, proteins and nucleic acids. Formation of reactive oxygen species (ROS) in hepatocytes is reported to undergo hepatotoxicity. Consequently, this hepatic cell toxicity leads to a range of liver diseases such as ischemia–reperfusion injury, fibrosis and liver failure [10] oxidative stress appears to play an important role in liver injury[11] .

Human body is equipped with various antioxidants viz. superoxide dismutase (SOD), glutathione peroxidase (GPx), catalase (CAT), glutathione (GSH), ascorbic acid (Vitamin C), α -tocopherol (Vitamin E), etc., which can counteract the deleterious action of ROS and protect from cellular and molecular damage [12]. Antioxidants act as radical scavengers inhibiting LPO and other free radical-mediated processes thereby protecting the human body from various diseases [13].

Various molecules can inhibit the formation of free radicals associated with carcinogenesis. Bioactive compounds from plant origin have the potential to subside the biochemical imbalances induced by various toxins associated with free radicals. They provide protection without causing any side effects and therefore, development of drugs from plant products is desired. Many plant extracts and plant products have been identified as good protectors against the free radicals by triggering antioxidant gene expression [14]. For that account natural antioxidants from plant sources have been viewed as promising therapeutic drugs [15].

Silymarin (SIL) is a standardized extract from the milk thistle *Silybum marianum* (L) is composed of many polyphenolic flavonoids, including silibinin (the major one), isosilybin,

silychristin and silidianin[16]. It's reported that consumption of silymarin is safe and non-toxic in animals and humans [17-18] and there is no known LD50 for silymarin [19]. It is a strong antioxidant capable of scavenging free-radicals [20] and several short-term studies have suggested that silymarin may be a potent anti carcinogenic agent [21]. In addition, several recent studies have shown the potential cancer preventive and therapeutic efficacy of Silybinin in different animal models and cell culture systems [22-23].

Silymarin (SIL) has been clinically used for its beneficial effects on various types of acute and chronic liver diseases such as alcohol or drug intoxication, mushroom poisoning and hepatitis C virus, whose pathogenesis involves an inflammatory response [24-25]), spleen and gallbladder disorders [26]. In United States, 10–15% of patients attending liver disease clinics reported having taken milk-thistle derivatives [27]. Over the years numerous animal models have been discovered as incubators of primarily human tumors, including newborn Syrian hamsters, mice, and rats. In addition, SIL protects experimental animals from various hepatotoxicants, such as CC_{14} , acetaminophen and phalloidin, and has been shown to have anti cholestatic properties [28]. Additionally, silymarin proved to be protective against several hepatotoxicants such as carbon tetrachloride [29] and D-galactosamine (GalN) [30] in different animal model.

For the importance of silymarin in many fields, Studies presented in this research focus on the ability of silymarin (SMN), a phytochemical extract of the milk thistle plant, to reduce or prevent liver damage which is a common side effect observed when rats are treated with DMBA.

MATERIALS AND METHODS

Chemicals:

DMBA was obtained from Sigma–Aldrich Chemicals (St. Louis, MO, USA). Silymarin (milk thistle powder containing 80% silymarin) was purchased from Bulk Nutrition (Northborough, MA, USA). All other chemicals and reagents including solvents were of high purity and of analytical grade used were purchased from Sigma–Aldrich and used without further purification.

Animal and housing:

Forty adult male Albino rats (*Rattus norvegicus*), pathogen-free rats weighing 140 ± 9 g; obtained from the animal breeding colony of the High Institute of Public Health, Alexandria University, Alexandria, Egypt, were used throughout the study. They were quarantined and allowed to acclimate for a week prior to experimentation. All animals were housed in plastic cages after grouping in batches of ten under standard laboratory conditions of a 12-h light/dark cycle in a temperature- and humidity-controlled room. They were supplied with standard laboratory chow and water *ad libitum*. The experimental procedures were conducted in accordance with the guide lines of Animal Ethics Committee of the Alexandria University.

Experimental design:

After an acclimation period, the animals were randomly divided into four equal groups (n=10, each). The animals were administered DMBA at a dose of (100 mg kg⁻¹ body weight) [31] only followed by doses of silymarin (200 mg/kg) [32] after 48 h of toxicant administration for a period of 12 weeks. At the end of the experiment, the animals were sacrificed by cervical dislocation, and hepatic enzymes parameters were performed and Liver samples were dissected out and washed immediately with ice-cold saline to remove as much blood as possible.

Hence, our treatment groups were as follows:

Group I: was given normal saline daily for a period of 12 weeks.

Groups II: Rats were orally administered silymarin (200 mg/kg) daily for a period of 12 weeks.

Group III: Rats were treated orally with a single dose of DMBA (100 mg kg⁻¹ body weight) in olive oil (intragastrically).

Group IV: was treated orally with a single dose of DMBA (100 mg kg⁻¹ body weight) in olive oil followed by silymarin (200 mg/kg).

During the treatment period body weight of the animals were monitored daily.

Activities of serum marker enzymes:

Blood samples were collected from hearts of rats using a syringe with 24-gauge needle under ether anesthesia. Centrifuged and serum was isolated to determine the activities of serum aspartate aminotransferase (AST), alanine aminotransferase (ALT) [33]. Alkaline phosphatase (ALP) was assayed according to the method of Kind and King [34].

Histopathological studies:

For qualitative analysis of liver histology, Parts of hepatic lobe obtained from each rats in different groups were fixed in 10% formalin solution and dehydrated in ascending grades of alcohol and embedded in paraffin. Sections at 4 μm-thicknesses were taken, stained with hematoxylin and eosin (H&E) as well as Masson trichrome stain for hepatocyte fibrosis, were observed under the light microscope (Olympus, Tokyo, Japan).

Transmission electron microscopy:

Electron microscopic examinations of liver tissues assessment was used to complete the study of liver damage. For this purpose Liver specimens (n=5) from each group were fixed for 24hr. in Formalin-Glutaraldehyde (4F₁G) then rinsed in phosphate buffer solution (pH 7.4) at 4°C for 3 hours. Specimens were then postfixed for 2 hr. in 2% Osmium tetroxide (OsO₄), and then the specimens were washed with phosphate buffer several times for 10 min. Specimens were dehydrated in a graded of ethanol series, followed by propylene oxide, and embedded in Araldite-Epon mixture. Sections were cut on LKB-III ultramicrotome. Grids were double stained

with uranyl acetate for ½ hour and lead citrate for 20-30 min. [35], and were examined by Jeol 100 CX electron microscope.

Statistical analysis:

The variability of results was expressed as the mean ± standard error (X±S.E.). The significance of differences between mean values was determined using one way analysis of variance (ANOVA) and Student’s t-test.

RESULTS

The effects of DMBA on general rat's health:

During the experiment, rats in the control group and in the silymarin treated group appeared healthy, did not show any sign of toxicity or death. However, DMBA treated rats showed varying degrees of clinical signs after dosing. The signs included decreasing activity, increasing weakness, less food intake, yellow and soiled fur, dark red eyeball, mild tremor, diarrhea and and two rats died in the second and third weeks of dosing, respectively.

Evaluation of body, absolute and relative liver weight:

During the treatment, bodyweight of DMBA exposed animals significantly decreased ($p<0.001$) versus the control group (Table 1). As a consequence, the animals gained less body weight than controls ($p<0.001$).

Table 1: Effects of silymarin on growth parameters of rats exposed to DMBA.

Parameter and treatments	Initial body weights (g)	Final body weights (g)	Weight gain (%)	Absolute liver weight (g)	Relative liver weight (g/100 g b.w)
Control (C)	162.837 ±7.65	230.7±4.93 _b	40.27±2.46 ^a	9.94±0.41 ^a	3.51±0.08 ^a
DMBA	161.67±5.81	140.7±4.69	29.58±1.89 ^b	6.97±0.33 ^b	3.25±0.06 ^b
silymarin	161.7±5.29	220.66±7.44	40.00±2.75 ^a	9.03±0.42 ^a	3.38±0.08 ^{ab}
silymarin + DMBA	162.7±4.60	209.57±7.79 _{ab}	35.99±2.59 ^{ab}	8.10±0.21 ^b	3.38±0.08 ^{ab}

Values are mean ± SD for 7 rats in each group.

a,b, Values are not sharing a common superscript letter (a,b) differ significantly at $p<0.05$.

DMBA treatment also decreased the absolute and relative liver weight. However, when the diet was supplemented with silymarin a partial recovery occurred in body weight ($p<0.01$). (Table 1) Compared to controls, silymarin treated group showed no significant changes in body and organ weights.

Biochemical indicators of liver function:

The activities of AST, ALT and ALP were estimated in serum samples as the liver function markers. These results are given in Table 2. No significant change in AST, ALT and ALP level were observed in the silymarin groups as compared to the control group. The DMBA treatment markedly affected the liver specific enzymes. It was found that administration of DMBA induced significant increase in the enzymatic activities of AST, ALT and ALP ($P \leq 0.05$) as compared to the control group. However, a significant decrease was observed in above serum activities of rats given silymarin + DMBA compared with the alone DMBA treated groups ($p \leq 0.05$).

Table: 2 Effects of DMBA and silymarin on serum enzyme activities of liver in rat.

Groups	AST U/L	ALT U/L	ALP U/L
control	127.18 ± 11.29	68.65 ± 5.57	278.5±37.6
DMBA	397.39 ± 21.37 ^a	256.46 ± 8.60 ^a	385.0±43.9 ^a
silymarin	131.65 ± 12.59	66.44 ± 9.23	247.4±31.4
silymarin + DMBA	156.3±28.7 ^b	77.69 ± 6.90 ^b	293.2±35.0 ^b

Each value represents the mean ±SEM of 7 animals.
 a Significantly different from control group ($p < 0.05$).
 b Significantly different from DMBA group ($p < 0.05$).

Table 3: The existence of some pathological lesions in liver tissues of different treatment groups

	Vacuolar degeneration	Inflammatory cell infiltration	Congestion	Necrosis
Control	0	0	0	0
DMBA	+++	+++	++	+++
silymarin + DMBA	+	0	0	+
silymarin	0	0	0	0

Damage grades are as follows: ∅ (absent), + (mild), ++ (moderate) and +++ (severe). (The livers of seven animals in each group were examined).

Histopathological findings:

The light microscopy examination of the transverse section of control and silymarin rat liver clearly illustrates complete normal architecture, hepatic lobules with well formed hepatocytes with distinct portal triads. Hepatic cells were arranged in cord like fashion, which are separated by sinusoids and central vein was seen clear (Fig. 1A&B). H&E-stained liver sections from rats receiving DMBA revealed exhibiting distortion in the arrangement of hepatocytes around the central vein, congestion of sinusoids around central vein regions, presence of large areas of necrosis with hemorrhage and neutrophil infiltration (Fig. 1C). Ballooning and degeneration in hepatic plates and loss of cellular boundaries Congestion were

seen (Fig.1D). Microscopic examinations showed that the severe hepatic lesions induced by DMBA were remarkably reduced by the treatment with silymarin (The histological appearance of the group was quite similar to that of the control group) (Fig. 1 E). These findings were in good agreement with the results of the hepatic marker enzymes.

Furthermore, histopathological changes (fibrosis) occurred in DMBA - intoxicated rat livers, and their prevention by treatment with silymarin was observed, as shown in Fig. 2 (Masson trichrome stain). In the normal control and silymarin-treated groups, liver sections showed normal hepatic cells without fibrosis (Figs. 2A). The livers of rat treated with DMBA showed numerous hepatic lobules surrounded by thick fibrotic tissue, resulting in the formation of continuous fibrotic septa. The collagen of these fibrotic tissues showed a green color when stained by Masson's Trichrome (Fig. 2B).

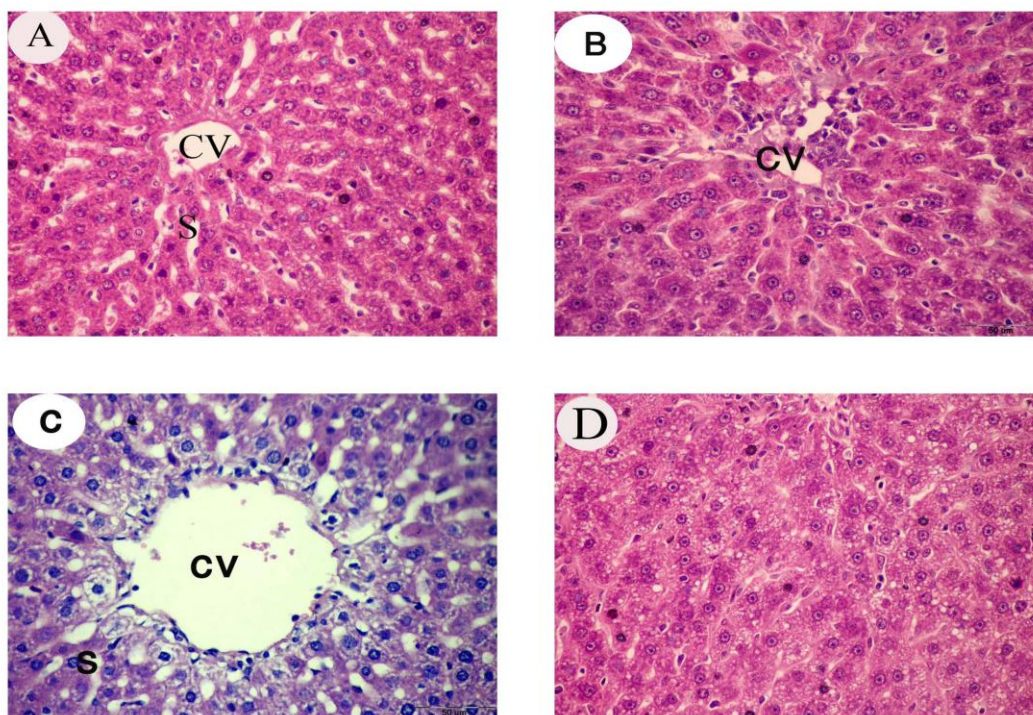


Fig. 1. Hematoxylin and eosin-stained sections of rat liver: (A&B) The control rats and animals treated with silymarin, show normal lobular architecture, it is composed of hexagonal or pentagonal (Hc) arranged in strands around the central vein). and are separated by sinusoids containing Kupffer cells.(C) Animals treated with DMBA showed severe signs of liver damage, some hepatocytes with cytoplasmic vacuoles others with binucleated cells and extensive necrosis, the central vein (CV) was enlarged and clusters of inflammatory cells. (D) Rats treated with silymarin and DMBA, showing normal hepatocytes with mild portal inflammation.

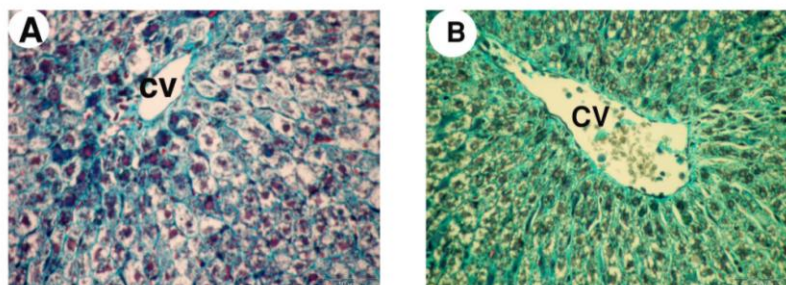


Fig 2: Histopathological changes of fibrosis occurred in DMBA -intoxication and prevention by the treatment with silymarin (Masson Trichrome stain, 200X). (A) Normal control and (B) DMBA.

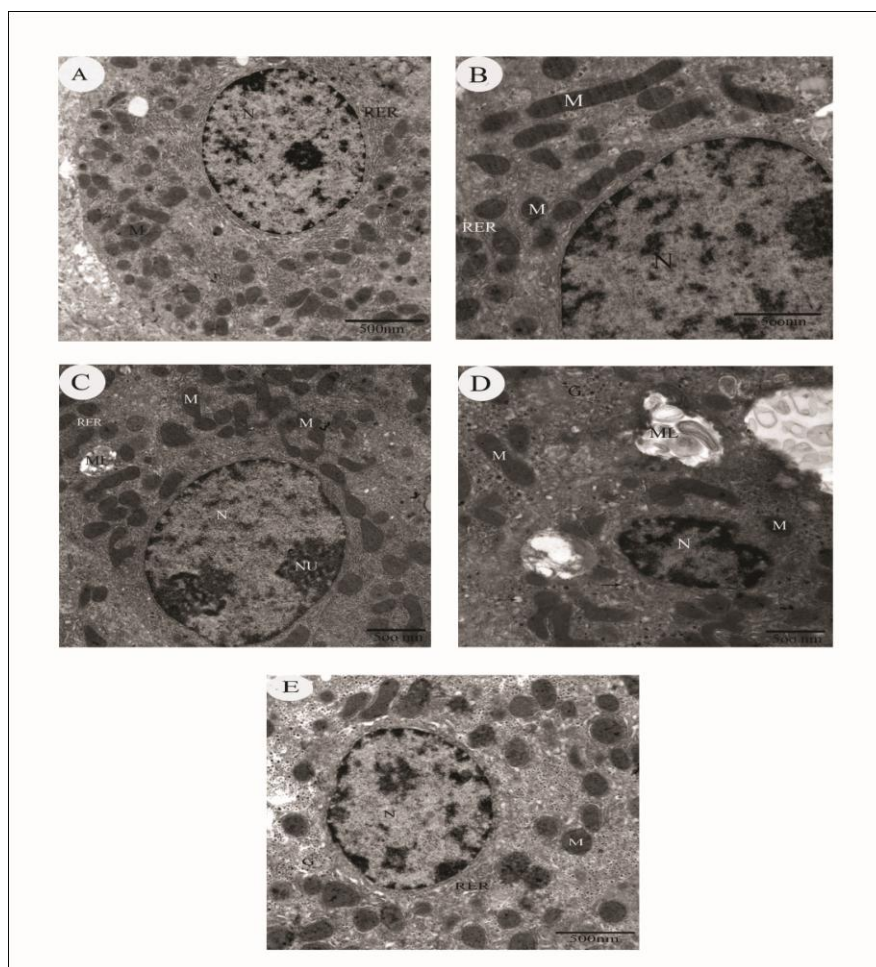


Fig. 3. Transmission electron microscopy of hepatocytes of control and experimental groups of rats. Transmission electron micrographs of control (A) and silymarin (B) rats, hepatic tissue sections were showed a normal aspect of around nucleus, nuclear envelope; mitochondria are well preserved, with a dense matrix and normally organized cristae and endoplasmic reticulum. Electron micrograph of the liver lobule from DMBA treated rat(C&D). Note area of necrosis with enlarged nuclei with multiple nucleoli, heterochromatin highly decreased, and loss of organelles. Depletion of glycogen content; collagen-like fibrous materials were seen(which

contains a myelin figures). Electron micrograph of silymarin + DMBA (E) treated rat hepatocyte, administered. Illustrate characteristic of normal hepatocyte architecture showing normal round nucleus, numbers of mitochondria. Some strands of endoplasmic reticulum and glycogen are also evident. G, glycogen rosettes; M, Mitochondria; RER, rough Endoplasmic reticulum, nucleus (N).

Ultrastructural liver changes:

Hepatocytes of control group rats showing the normal cellular organelles. Mitochondria and endoplasmic reticulum were abundant in hepatocytes, nucleus with one or two nucleoli and intact nuclear membrane and nuclear chromatin, which is round and big, found in the center of the hepatocytes. The hepatocytes are exposed on each side to the sinusoids, which are lined by a discontinuous layer of fenestrated endothelial cells. The endothelial cells are separated from the underlying hepatocyte surface by space of Disse is continuous with the sinusoidal lumen, thus of the hepatocyte that faces the space of Disse bears many irregular microvilli protruding in that space (Fig. 3A). Similar architecture is observed in the electron micrograph of control group of rats treated with silymarin (Fig. 3B).

The ultrastructural changes in hepatocytes after DMBA included damaged villi on the cell surface, swelling of the hepatocytes with loss of plasma membranes. chromatin density lost its homogeneity in nucleus (Fig. 3C). Also, pyknotic nuclei with damaged nuclear membrane (Fig. 3D). The mitochondria changed their size and shape, i.e. they became polymorphous with the thickening of their matrix. Weak swellings of endoplasmic reticulum were occurred. All hepatocytes showed only a few scattered glycogen granules were observed among dilated smooth endoplasmic reticulum. Also, Deposits of collagen-like fibrous materials were seen (Fig. 4c). The electron micrograph of hepatocyte of rats treated with silymarin + DMBA showing, no pathological findings. Mitochondria and nucleus were observed in normal structure, accumulation of glycogen and parallel rough endoplasmic reticulum cisternae with ribosomes were seen. (Fig.3E). and are comparable with control group of rats.

DISCUSSION

Hepatic injury is a common pathological feature which exists in many liver diseases. Liver fibrosis, cirrhosis and even liver cancer could result from the long existence of hepatic injury. Therefore, prevention and treatment of hepatic injury is a key to treating liver diseases clinically [36]. Dimethyl benz(a) anthracene is one of the PAHs and is a well-known environmental toxin [3] and carcinogen [7]. In this study we aimed to investigate the hepatoprotective effects of silymarin against DMBA -induced liver injury in rats.

In the present study, the rats treated with DMBA showed many changes and certain external symptoms in the general behavior of the animals. The major symptoms developed were loss of appetite, loss of body weight, weakness of leg muscles and decreased spontaneous activity. In agreement with our observation, De Wys et al. [37] reported that roughly one-half of

all patients with disseminated cancer had lost some weight at all time of presentation and about one-third had lost more than 5% of their usual body weight in the preceding months.

Increases in serum ALT, AST and ALP levels have been attributed to hepatic structural damage because these enzymes are normally localized to the cytoplasm and released into the circulation after cellular damage has occurred [38]. The present data showed that, serum ALT, AST and ALP levels rapidly increase in parallel with DMBA injection, indicating the induction of acute hepatotoxicity by DMBA. The present results are in agreement with the finding of [39] who reported an increase in the activity of alkaline phosphatase due to NDEA treatment in rat liver. Also, Muqbil and Banu [40] have reported increase in tissue marker enzymes glutamate oxaloacetate transaminase (GOT), glutamate pyruvate transaminase (GPT) and ALP in Swiss Albino rats after treatment with (DMBA). Administration of silymarin attenuated the increased levels of the serum enzymes, produced by DMBA and caused a subsequent recovery towards normalization in the form of recovery [41] of serum parameters by different test samples. Silymarin treatment was the most effective treatment to counteract DMBA-induced hepatic injury as indicated by liver function tests (ALT, AST, and ALP) were effectively restored to the normal control values, suggesting that Silymarin is beneficial for liver regeneration to reverse liver injury.

The liver is a major inflammatory organ, and inflammatory processes contribute to a number of pathological events after exposure to various hepatotoxins. As shown in our results DMBA- induced liver damage including hepatocyte necrosis, vacuolization and Kupffer cells around the central vein as well as hepatocyte fibrosis. In agreement with above report, [42] reported that N-nitrosomorpholine (NNM) induced hepatocellular carcinoma in the liver of rat. Hayashi et al. [43] induced hepatocellular adenomas in male rat treated with diethylnitrosamine (DEN). However, treatment with silymarin decreased these hepatotoxicity characteristics in rat liver, suggesting that silymarin provided protection against DMBA - induced liver injury.

In the present study, the ultrastructural study revealed significant loss of normal cellular architecture of liver. This alteration involved both the nucleus and cytoplasmic organelles. The hepatocyte nuclear envelope was evidently irregular in rats treated with DMBA. De Brito and Miguel [44] mentioned that irregularity of nuclear form provides an increase area of contact between the nucleus and the cytoplasm and in some cases this seems to denote increased nucleocytoplasmic exchanges and increased metabolic activity. A similar observation has been reported by Sadek et al. [45] in the liver of DMBA treated chicken. Cole et al. [46] confirmed the previous results where they observed marked irregular nuclear chromatin condensation in human, rats and mice hepatocytes in primary culture treated with aflatoxin B1. Moreover, the electron micrographs of the experimental group of the animals received DMBA alone revealed large degree of pleomorphic mitochondria. Starkove and Wallace [47] pointed out that swelling of mitochondria and leak of their inner membranes were due to the effect of fluoro-chemicals on rat liver. A further support for our observation is reported by De Brito and Miguel[44] who found fragmentation of mitochondrial membranes in hepatocyte of Rana after aldrin administration. Also, Sauer et al. [48] reported reduced matrix density of the mitochondria in the liver of rats after injection of 1-nitronaphthaline. The present study revealed that rough

endoplasmic reticulum (RER) in hepatic cells of rats that injected with DMBA had undergone certain definable morphological changes. Our results showed that treatment of rats with Silymarin effectively protected the animals against DMBA -induced hepatic damage, as evidenced by reduced these histopathological changes.

Formation of reactive oxygen species (ROS) in hepatocytes is reported to undergo hepatotoxicity. Consequently, this hepatic cell toxicity leads to a range of liver diseases such as ischemia–reperfusion injury, fibrosis and liver failure [10] oxidative stress appears to play an important role in liver injury [11]. ROS is majorly generated in the mitochondria leading to serious damage to macromolecules of cellular system i.e. lipids, proteins, and DNA [49]. Mitochondria induced ROS plays an important role in the early stages of apoptosis. There are two principle pathways for apoptosis: one requires the activation of cell surface receptors such as Fas, while the other directly targets mitochondria. Both the pathways subsequently activate proteolytic enzymes called effector caspase-3 that mediate rapid dismantling of cellular organelles and architecture [50]. ROS generated during environmental pollutants metabolism are detoxified by the antioxidants present in the body leading to a state of equilibrium. However, owing to inadequate antioxidant defense or overproduction of ROS, the equilibrium tilts favoring an upsurge of ROS which further culminates in oxidative stress.

The environment represents a key contributor to human health and disease. Exposure to many substances such as pollutants and chemicals (environmental stressors), have detrimental effects on health and are considered to contribute substantially to most diseases of major public health significance. Environmental diseases are those in general aroused or exacerbated by exposure to environmental stressors and include cancer, chronic lung disease, diabetes and neurodegeneration. Several reports have indicated that an important mechanism in hepatoprotective effects may be related to the capacities of antioxidants to scavenge reactive oxygen species [51] . A number of biologically active phytochemicals have been identified in plant foods [52]. The antioxidative and free-radical scavenging activities of many substances have been assessed, and many substances that possess anti-hepatotoxic activity also show strong antioxidative activity [53].

Herbs have recently attracted attention as health beneficial food and as source materials for drug development. They offer a potential natural health care approach that focuses on protecting and restoring the health. Recently herbal medicines are being increasingly utilized to treat a wide variety of clinical diseases, including liver diseases [54] with relatively little knowledge regarding their modes of action [55].

Milk thistle extract has becoming an increasingly popular phytochemical prescribed by herbalists throughout the world to maintain liver health. The efficacy of silymarin has been shown against chemically induced carcinogenesis, growth of tumor xenograft, as well as in various transgenic models. Agarwal et al., [56] demonstrate the activity of silymarin against 12-O-tetradecanoyl-phorbol- 13-acetate (TPA) induced tumor promotion by inhibiting the activity and expression of epidermal ornithine decarboxylase. Further studies suggested the important

role of silymarin in inhibiting the chemical- and UV-induced skin carcinogenesis [57]. Gu et al., [58] have shown that topical or dietary silibinin treatment causes a strong protection against UVB-induced photocarcinogenesis by inhibiting cell proliferation, inflammation and angiogenesis in SKH-1 hairless mice. With regard to prostate cancer, it has been shown that dietary administration of silymarin significantly decreased the incidence of 3, 2-dimethyl-4-aminobiphenyl -induced prostatic adenocarcinoma in male F344 rats [59]. Moreover, dietary administration of silibinin inhibits the advanced human prostate tumor xenograft growth in athymic nude mice by exhibiting anti-proliferative, pro-apoptotic, and anti-angiogenic efficacy against prostate tumor [60]. also , dietary silibinin inhibits prostate tumor growth and progression in transgenic adenocarcinoma of the mouse prostate (TRAMP) mice by modulating the expression of CDKs, CDKIs, and insulin like growth factor (IGF)-1 and IGF binding protein (IGFBP)-3 [22]. In other studies, administration of silibinin significantly inhibits Nbutyl- N-(4-hydroxybutyl) nitrosamine induced urinary bladder carcinogenesis in male ICR mice by causing cell cycle arrest and induction of apoptosis [61]. Also silibinin inhibits the growth of human bladder tumor xenograft in athymic nude mice by down-regulating survivin and an increase in p53 expression together with enhanced apoptosis [62]. Vinh et al. [63] have shown that administration of silymarin reduces the labeling index for BrdU and the cyclin D1-positive cell ratio in various bladder lesions.

Silymarin, an antioxidant flavonoid complex isolated from the seed of milk thistle (*Silybum marianum*, Compositae), has been used to treat hepatotoxicity diseases in clinical practice for at least two decades. Silymarin has powerful free-radical scavenging properties and regulates intracellular GSH levels [64]. The biological activities of SMN, a major constituent of Milk thistle extract, have been attributed to its antioxidant activity and biological effects that are downstream of this activity [65] including stimulation of phase II detoxification pathways [66]. The mechanisms that have been proposed include functioning as an antioxidative scavenger of free radicals (mainly active toward HO and HOCl and less so for H₂O₂ or O₂⁻) and as a regulator of immune functions by modulating cytokine production [67-68]. Silymarin has powerful free-radical scavenging properties and regulates intracellular GSH levels [64]. Also, The mechanisms by which silymarin exerts its hepatoprotective action appear to be multifactorial in origin [69]. Silymarin stabilizes the membrane structure of hepatocytes and thus prevents toxins from entering the cell through enterohepatic recirculation [70]. In addition, silymarin prevents lipid peroxide formation in hepatocytes due to its free radical scavenger activity and its stimulation for antioxidants [71].

In conclusion, Enzymes evaluations and histopathological changes in this study showed that DMBA affects hepatocytes in rats. We found that Silymarin caused a protective effect against DMBA -induced liver damage. We suggest that Silymarin may be used to protect against toxic effects of DMBA and other chemical agents in liver.

REFERENCES

- [1] Neef JM .Fundamental of Aquatic Toxicology. New York: Hemisphere Publication 1985; 416–454.

- [2] Nebert DN, Dalton TP, Okey AB, Gonzalez FJ .The Journal of Biological Chemistry 2004; 279: 23847–23850.
- [3] Nagar S, Zalatoris JJ, Blanchard RL .Pharmacogenetics 2004; 14(8): 487–499.
- [4] Hsue SS, Chen YK, Lin LM. Oral Oncology 2008; 44: 43–49.
- [5] Donovan K A, PhD, MBA, Paul B. Jacobsen, PhD, Michael A. Andrykowski, PhD, Erin M. Winters, MA, Lodovico Balducci, MD, Uzma Malik, MD, Daniel Kenady, MD, Patrick McGrath, MD. Journal of Pain and Symptom Management 2004; 28 4: 373-380.
- [6] Lichius JJ, Muth C .Planta Medica 1997; 63: 307–310.
- [7] Li N, Chen X, Liao J, et al. Carcinogenesis 2003; 23: 1307–1313.
- [8] Bishayee A, Oinam S, Basu M, Chatterjee M. Breast Cancer Research Treatment 2000; 63 (2):133–145.
- [9] Ray G, Batra S, Shukla NK, Deo S, Raina V, Ashok S, Husain SA.Breast Cancer Research Treatment 2000 ;59: 163–170.
- [10] Novo E, Parola M .Fibrogenesis and Tissue Repair 2008; 1:5.
- [11] Sheu SS, Nauduri D, Anders MW .Biochimica ef Biophysica Acta 2006; 1762 (2): 256-265.
- [12] Cotgreave Ibb, Moldens P, Orrenius S. Annual Review of Pharmacology and Toxicology 1988; 128:189–212.
- [13] Jagetia GC, Rao SK. Biological and Pharmaceutical Bulletin 2006; 29: 460-466.
- [14] Mittal A, Pathania V, Agarwal PK Prasad J, Singh S, Goel HC . Journal Ethanopharmacol 2001; 76: 53–262.
- [15] Vijayavel K, Anbuselvam C, Balasubramanian MP. Chemico-Biological Interactions 2006; 163: 170–175.
- [16] Wu JW, Lin LC, Tsai TH .Journal Ethnopharmacol 2009; 121:185–193.
- [17] Singh RP Dhanalakshmi S, Tyagi AK, Chan DC, Agarwal C, Agarwal R.Cancer Research 2002 ; 62: 3063–3069.
- [18] Agarwal C, Singh RP, Dhanalakshmi S, Tyagi AK, Tecklenburg M, Sclafani RA, Agarwal R. Oncogene 2003; 22: 8271–8282.
- [19] Gazak R, Walterova D, Kren V. Current Medicinal Chemistry 2007; 14: 315–338.
- [20] Wellington K, Jarvis B .Bio Drugs 2001; 15:465–489.
- [21] Kren V, Walterova D. Biomed Pap Med Fac Univ Palacky Olomouc Czech Repub 2005; 149(1):29–41.
- [22] Raina KMJ, Blouin RP, Singh N, Majeed G, Deep L, Varghese LM, Glode NM, Greenberg D, Hwang P, Cohen MN, Pollak R, Agarwal .Cancer Research 2007 ; 67: 11083–11091.
- [23] Singh RP, Gu M, Agarwal R .Cancer Research 2008; 68:2043–2050.
- [24] Wen Z, Dumas TE, Schrieber SJ, Hawke RL, Fried MW, Smith PC .Drug Metabolism and Disposition 2008 ;36:65–72.
- [25] Ferenci P, Scherzer TM, Kerschner H, Rutter K, Beinhardt S, Hofer H, Schoniger-Hekele M, Holzmann H, Steindl-Munda P. Gastroenterology 2008;135: 1561–1567.
- [26] Rainone F. American Family Physician 2005; 72: 1285.
- [27] Hoofnagle JH .Hepatology 2005; 42: 4.
- [28] Crocenzi FA, Roma MG. Current Medicinal Chemistry 2006; 13: 1055–1074.
- [29] Lette´ron P, Labbe G, Degott C, Berson A, Fromenty B, Delaforge M, et al. Biochemical Pharmacology 1990; 39:2027–2034.

- [30] Conti M, Malandrino S, Magistretti MJ). Japanese Journal of Pharmacology 1992; 60:315–321.
- [31] Reitman S, Frankel S .American Journal Of Clinical Pathology 1957; 28: 56–63.
- [32] Kind PRN, King EJ .Journal of Clinical Pathology 1954; 7: 322–330.
- [33] Reynolds ES .Journal of Cell Biology 1963; 17: 203-212.
- [34] Yuan HD, Jin GZ, Piao GC .Journal of Ethnopharmacology 2010; 127: 528–533.
- [35] De Wys WD, Begg C, Lavin PT, Band PR, Bennett JM, Bertino JR, Cohen MH, Douglass HD, Engston PF, et al. The American Journal of Medicine 1980; 69: 491-497.
- [36] Recknagel RO, Glende EA, Dolak JA, Waller RL .Pharmacology &. Therapeutic 1989; 43: 139-154.
- [37] Bansal AK, Bansal M, Soni G, Bhatnager D. Chemico- Biological Interactions 2005; 156: 101-111.
- [38] Muqbil I , Banu N . Cancer Letters 2006; 240: 213-220.
- [39] Yadav NP, Dixit VK .Journal of Ethnopharmacology 2003; 86: 197-202.
- [40] Jeong JS, Lee SH, Jung KJ, Choi YC, Park WY, Kim SS .Experimental Molecular Pathology 2003 ; 74: 74-83.
- [41] Hayashi M, Ohnota H, Tamura T, Kuroda J, Shibata N, Akahane M, Moriwaki H, Machida N , Mitsumori K. Archives of Toxicology 2004; 78: 460-466.
- [42] De Brito-Gitirana L, Miguel NC. Experimental and Toxicological Pathology 2000; 52: 339-347.
- [43] Sadek IA, Ismail HM, Sallam HN, Salem M. East Meditenanean Health Journal 1995; 1: 241-274.
- [44] Cole KE, Hsu IC, Trump BF .Cancer Research 1986; 46: 1290-1296.
- [45] Starkove AA , Wallace KB Toxicological Sciences 2002; 66: 244-252.
- [46] Sauer JM, Eversole RR, Lehmann CL, Johnson DE and Beuving LJ .Toxicology Letters 1997; 90: 19-27.
- [47] Orrenius S .Drug Metabolism Reviews 2007; 39: 443–455.
- [48] Cain K, Bratton SB, Cohen GM. Biochimie 2002; 84: 203–214.
- [49] Tsai CF, Hsu YW, Chen WK, Chang WH, Yen CC, Ho YC, Lu FJ. Food and Chemical Toxicology 2009; 47:2031– 2036.
- [50] Lampe JW, Chang JL. Seminars in cancer biology 2007; 17(5) 347-353.
- [51] Hwang YP,ChoiJH, Jeong HG. Food and Chemical Toxicology 2009; 47:75–81.
- [52] Gupta M, Majumder UK, Thamilselvan V, Manikandan, Senthilkumar GP, Suresh R, et al. Iranian Journal Pharmacology Therapeutics 2007; 6:5–9.
- [53] Jeong HG, You HJ, Park SJ, Moon AR, Chung YC, Kang SK, et al. Pharmaceutical Research 2002 ; 221-227.
- [54] Agarwal RS, Katiyar DW, Lundgren H, Mukhtar. Carcinogenesis 1994; 15: 1099–1103.
- [55] Deep GR, Agarwal. Integrative Cancer Therapies 2007; 6: 130–145.
- [56] Gu MRP, Singh S, Dhanalakshmi C, Agarwal R, Agarwal. Cancer Research 2007; 67:3483–3491.
- [57] Kohno HR, Suzuki S, Sugie H, Tsuda T, Tanaka. Clinical Cancer Research 2005; 11: 4962–4967.
- [58] Agarwal RC, Agarwal H, Ichikawa RP, Singh BB, Aggarwal. Anticancer Research 2006; 26:4457–4498.

- [59] Tyagi A, Raina K, Singh RP, Gu M, Agarwal C, Harrison G, Glode LM, Agarwal R *Molecular Cancer Therapeutics* 2007 ;6:3248–3255.
- [60] Singh RPA, Tyagi G, Sharma S, Mohan R, Agarwal .*Clinical Cancer Research* 2008; 14:300–308.
- [61] Vinh PQ, Sugie S, Tanaka T, Hara A, Yamada Y, Katayama M, Deguchi T, Mori, H. *Japanese Journal of Cancer Research* 2002 ; 93:42–49.
- [62] Shaker E, Mahmoud H, Mnaa S. *Food and Chemical Toxicology* 2010; 46: 803– 806.
- [63] Velussi M, Cernigoi AM, De Monte A, Dapas F, Caffau C, Zilli M. *Journal of Hepatology* 1997;26: 871-879.
- [64] Zhao J, Agarwal R.*Carcinogenesis* 1999; 20(11):2101-2108.
- [65] Ferenci P, Dragosics B, Dittrich H, et al. *Journal of Hepatology* 1989; 9(1): 105–113-58.
- [66] Luper S .*Journal of Alternative Medicine Review* 1998; 3: 410-421.
- [67] Mayer KE, Myers RP, Lee SS .*Journal of Viral Hepatitis* 2005; 12: 559–567.
- [68] Negi AS, Kumar JK, Luqman S, Shanker K, Gupta MM, Khanuja SP .*Medicinal Research Reviews* 2008 ; 28: 746–772.
- [69] Varga Z, Czompa A, Kakuk G, Antus S.*Phytotherapy Research* 2001 ;15: 608–612.