

Research Journal of Pharmaceutical, Biological and Chemical Sciences

Combined effects of Vitamin E and Vitamin C supplementation on cadmium induced testicular morphology and oxidative stress

Rekha D Kini^{*1}, Yogesh Tripathi², CV Raghuveer³, Sheila R Pai¹, Ramaswamy C⁴

¹ Dept. of Physiology, Kasturba Medical College, Mangalore, Manipal University, Karnataka

² Dept. of Physiology, Santhosh Medical College, New Delhi

³ Dept. of Pathology, Srinivas Medical College, Mangalore, Karnataka

⁴ Dept of Physiology, Saveetha Medical College, Saveetha Nagar, Thandalam, Chennai

ABSTRACT

Cadmium (Cd) is an environmental and industrial pollutant that affects the male reproductive system. Exposure to cadmium metal is known to induce the formation of reactive oxygen species (ROS) like superoxide radical, hydroxyl ion and hydrogen peroxide. Vitamin E is a lipid phase antioxidant & Vitamin C acts as a potent water soluble antioxidant by scavenging reactive oxygen species. The purpose of present study was to investigate the protective role of combined therapy of vitamin E & vitamin C on cadmium induced testicular damage. Animals were segregated into following 4 groups; Control(0.9% saline treated), Pre-treated control(Vit E & C treated in combination), cadmium treated(0.5mg/kg bw injected), pretreated with vitamin E(100mg/kg bw) & vitamin C(30mg/kg bw) for 30 days prior to cadmium treatment. After the desired protocol, rats were sacrificed & testes were removed for biochemical & histopathological evaluation. The levels of lipid peroxides (LPO) and glutathione (GSH) & superoxide dismutase (SOD) were detected in the tissue homogenates of rat testis. The level of lipid peroxidation (LPO) was high & GSH & SOD were low in cadmium treated rats compared to normal control. Pre-treatment with vitamin E & C in combination showed a protective effect by decreasing LPO & increasing GSH & SOD level. Present study showed the morphological changes like atrophy of tubules, edema & decreased spermatogenesis in the testis of rats. Pre-treatment with antioxidant showed the protective role against cadmium testicular damage. Pre-treatment with vitamin E & C combination was beneficial in protecting the testis from cadmium induced toxicity

Keywords: Cadmium, oxidative stress, antioxidants, lipid peroxide, glutathione

***Corresponding author**

Email: rekhadk2004@yahoo.com

INTRODUCTION

The humans are exposed to various types of environmental contaminants at different stages of their lifespan; the majority of these are harmful. Cadmium (Cd) is considered to be one of the most toxic heavy metals. Cadmium is a by-product of the mining and smelting of lead and zinc. It is used in nickel-cadmium batteries, dyes, plastics, electrochemistry and paint pigments. It can be found in soils because insecticides, fungicides, sludge and commercial fertilizers containing cadmium that are used in agriculture. Cadmium has been found to produce wide range of biochemical and physiological dysfunctions in humans and laboratory animals [1]. In addition, cadmium is carcinogenic metal to which humans are exposed through contaminated foods, water or air. Chronic cadmium poisoning can result in nephrotoxicity, osteoporosis, cardiovascular diseases, testicular necrosis, prostatic and testicular cancers, and renal failure and neurodegenerative conditions [2]. In Cadmium exposed mammals, many target organs are affected including the testes, brain, liver and kidneys [3, 4]. Rodent testes are more susceptible to cadmium toxicity than liver, as manifested in testicular damage without pathological changes to other organs [5]. Exposure to cadmium can negatively affect the male reproductive system via degenerative changes in testes, epididymis, and seminal vesicles. Cadmium is considered as ubiquitous toxic metal that induce oxidative damage by disturbing the peroxidant– antioxidant balance in the tissue [6]. Cadmium depletes many essential metal antioxidants including selenium in the body [7]. Many investigators proposed that one possible mechanism of cadmium toxicity is the disturbance of prooxidant and antioxidant balance by generation of reactive oxygen species (ROS) [8]. To counteract the damaging ROS, aerobic cells are provided with extensive antioxidant defense mechanisms. These consist mainly of antioxidant enzymes (e.g., superoxide dismutase, catalase, glutathione peroxidase etc) and small molecule antioxidant (e.g., glutathione, N-acetyl-cystein, vitamin E and vitamin C) [9]. Vitamin E is an important antioxidant residing in the cell membrane and well accepted as the first line defense against lipid peroxidation. Vitamin E interrupts the chain reaction involved in lipid peroxidation, and to delay lipid peroxidation by scavenging intermediate radicals such as lipid [9]. Vitamin C acts as a potent water soluble antioxidant by scavenging reactive oxygen species and reactive nitrogen species. In addition to scavenging action vitamin C can regenerate other small molecule antioxidants such as α - tocopherol, glutathione, urate from their respective radical species [10]. The aim of the present study is to throw light on cytoprotective effect of vitamin E & vitamin C in combination against cadmium induced testicular toxicity.

MATERIALS AND METHODS

Chemicals:

The cadmium chloride, Thiobarbituric acid, butylated hydroxytoluene, reduced glutathione, 5', 5'-dithiobis-2-nitro-benzoic acid were from Sigma (USA). Vitamin E from Merk Company limited, Bombay, India all other chemicals used were of analytical grade.

The present study was conducted following approval from Institutional Bioethical Committee and strict internationally accepted guidelines, for the usage of animals in

experimental study were followed. Inbred adult male albino rats of wistar strain weighing 200-300g were used in the present study. Animals were housed in polypropylene cages (4-5 rats per cage) under standard laboratory conditions and fed ad libitum with commercial rodent chow (Hindustan lever limited) and water.

Rats were randomly divided into 4 groups (8 rats in each group) as the following

Group I (Control group) receives 0.9% saline intraperitoneally

Group II (pre-treated control) received vitamin E (100mg/kg BW orally) & Vitamin C in combination for (30mg.kg BW orally) for 30 days

Group III (Cadmium treated) received a single dose of 0.5mg/kg BW cadmium chloride dissolved in 0.9% saline intraperitoneally & animals were sacrificed 15 days after cadmium administration

Group IV (vitamin E& C + cadmium group) pre-treated with Vitamin E & C for 30days & then administered cadmium chloride & animals were sacrificed 15 days after cadmium administration

Following the completion of the experimental protocol animals in each group were anaesthetized by injecting sodium Pentobarbitone (40mg/kg BW) intraperitoneally under aseptic condition. Laparotomy was performed and the reproductive organs were exposed. Both the testes were removed and cleaned of fat tissue and blood and kept in cold buffered saline (0.9%). In each group, right testis was cut into small pieces and used for biochemical analysis and left testis was used for histo-pathological studies. Pieces of the right testis were transferred into a glass homogenizer containing 10ml of cold phosphate buffer saline solution of pH 7.4. The tissue was homogenized using a manual homogenizer. The unbroken cells and cell debris were removed by centrifugation at 3000 rpm for 10 minutes by using Remi C 24 refrigerated centrifuge(- 4°C). The obtained supernatant was used for the GSH, SOD & lipid peroxide estimation. Left testis was put into a bottle containing Bouins solution for the histo-pathological analysis.

ESTIMATION OF TESTICULAR LIPID PEROXIDATION

Lipid peroxidation was estimated according to the method of Kartha & Krishnamurthy [11]. This assay is based on the reaction of TBA with malondialdehyde (MDA), one of the aldehyde products of lipid peroxidation.

ESTIMATION OF TISSUE GLUTATHIONE

Glutathione content in the tissue homogenate [10% w/v in 10mM potassium phosphate buffer (7.4pH)] was estimated by the method of Beutler et al [12].

Superoxide Dismutase Assay

Superoxide Dismutase (SOD) was estimated by original method of Beauchamp and Fridovich [13].

Histological slides preparation.

Specimens from testicular tissues were fixed in Bouins solution & dehydrated in ascending grades of ethanol alcohols, cleared in xylol, casted, blocked, cut at 2-5 μ m thickness and stained with hematoxylin-eosin for microscopic examination [14].

STATISTICAL ANALYSIS

Values were expressed in mean \pm SEM. SPSS version II was used for statistical analysis. Differences between groups were assessed by one-way analysis of variance. The Post Hoc (LSD) test was used for intergroup comparison. $P < 0.05$ was taken as significant.

RESULTS

Biochemical results:

The levels of LPO in the tissues homogenates of testes were significantly higher in cadmium-group than control group. Pre-treatment with vitamin E & vitamin C in combination prior to cadmium administration showed significant decrease in the level of lipid peroxide. The levels of GSH & SOD in the tissues homogenates of testes were significantly declined in Cadmium-group comparing with controls. In the rats, pretreated vitamins + cadmium group, the levels of GSH & SOD were significantly elevated in comparison with cadmium-treated group (Table-1).

Table 1: Effects of pretreatment with vitamin E & C in combination for 30days prior to cadmium administration on rat testis. The values are expressed as mean \pm SEM. In each group eight animals were used. NS= not significant versus Gr.I. * $p < 0.001$ versus Gr.I & Gr.II. $\blacklozenge\blacklozenge\blacklozenge$ $p < 0.001$ versus Gr.III**

Variable	Group I	Group II	Group III	Group IV
MDA(nmol/gm wet tissue)	5.113 \pm 0.277	5.121 \pm 0.261 ^{NS}	26.687 \pm 1.229 ^{***}	5.374 \pm 2.168 $\blacklozenge\blacklozenge\blacklozenge$
GSH(nmol/mg protein)	5.951 \pm 0.379	5.894 \pm 0.218 ^{NS}	3.570 \pm 0.08 ^{***}	5.775 \pm 0.341 $\blacklozenge\blacklozenge\blacklozenge$
SOD(units/gm protein)	12.451 \pm 0.510	12.472 \pm 0.428 ^{NS}	7.496 \pm 0.376 ^{***}	12.769 \pm 0.624 $\blacklozenge\blacklozenge\blacklozenge$

Histopathological results:

The testes of normal control rats showed the normal architecture of the testes(Fig-1). No detectable histological alterations showed in the testes of rats pretreated with vitamins in

combination. The testes of male albino rats intoxicated with cadmium chloride alone showed decreased spermatogenesis (less than 10% of tubule) & atrophy of the tubules (Fig-2). Testes of the rats pretreated with vitamin E & C in combination prior to cadmium administration were normal and showed spermatogenesis in more than 50% of the tubule & also interstitial cells were normal (Fig-3)

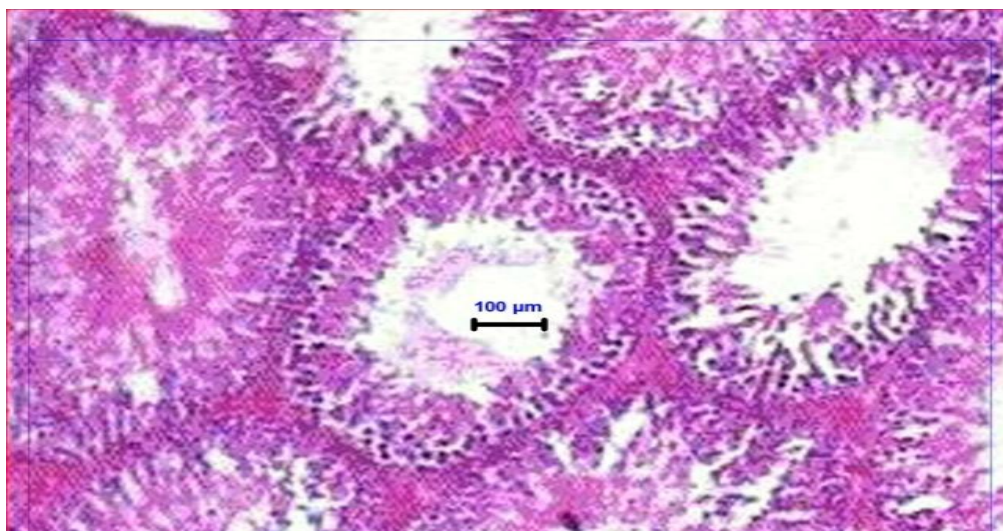


Fig:1. Testes of male albino rat treated with 0.9% saline showing normal structure of seminiferous tubules (H&E ;10X). Scale bar 100 μ m(Gr.I)

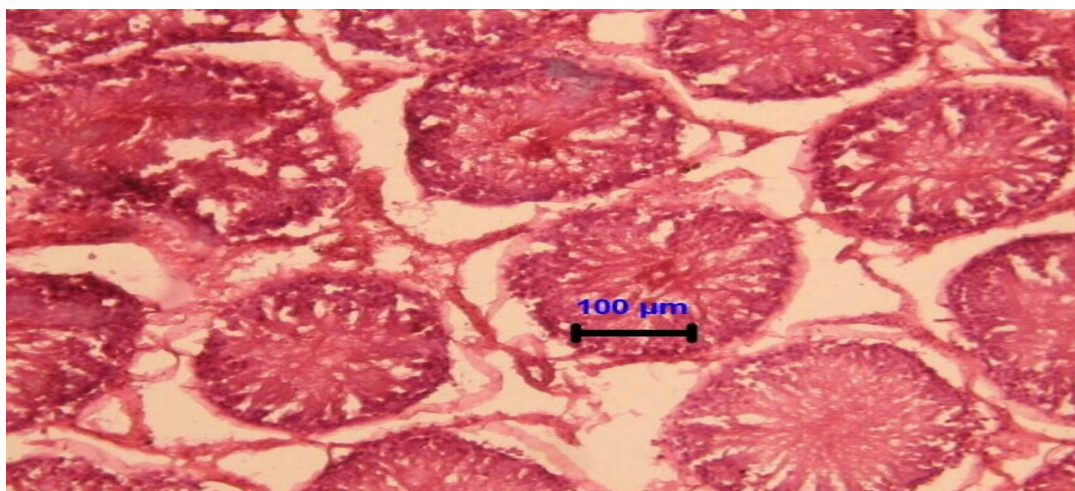


Figure 2. Testes of male albino rat intoxicated with cadmium chloride alone showing atrophy of the tubules. (H& E;10X). Scale bar 100 μ m(Gr.III)

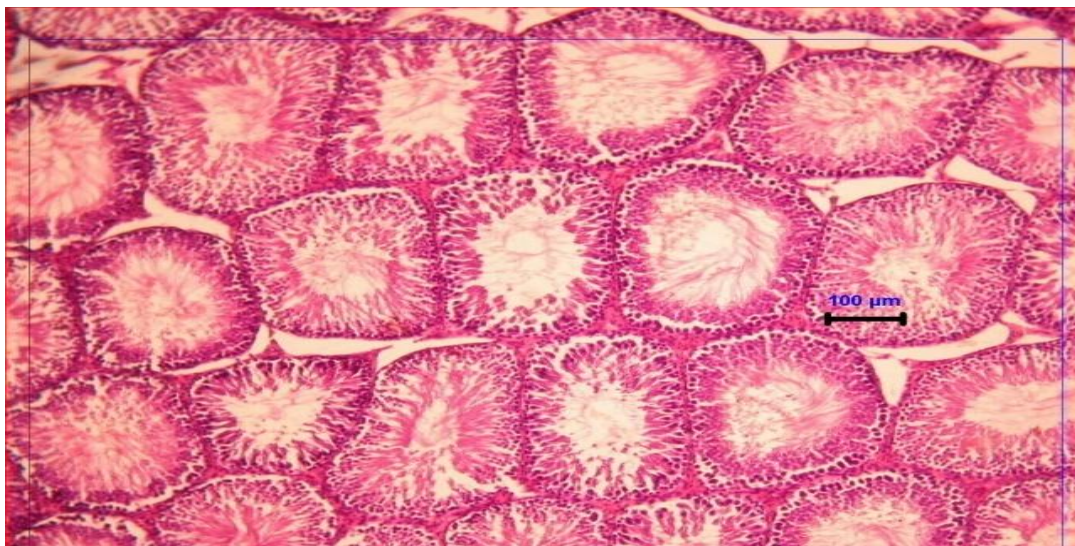


Figure 3: Testes of male albino rats pre-treated with vitamin E & C & cadmium chloride showing normal seminiferous tubules. (H& E; 10X). Scale bar 100μm(Gr.IV)

DISCUSSION

Cadmium is widely distributed in the environment because of its many industrial applications. The health risk to humans from acute and chronic cadmium exposure has been well documented. Previously, Mueller (1986) reported that single-dose cadmium administration increased lipid peroxidation and decreased GSH in the liver [15]. Many investigators reported that the reduction of GSH levels leads to elevation of LPO [16,17]. The present study demonstrated that the levels of GSH & SOD in the tissues homogenates of testes were significantly declined in cadmium-group comparing with controls. Various mechanisms were suggested to be responsible for the cadmium toxicity. One of these mechanism includes cadmium binding to-SH groups from cell membrane proteins, cytoplasmic proteins, and enzymes. In addition, cadmium can reduce activities of several enzymes including enzymes antioxidants. In addition, the authors showed that in vitro and in vivo cadmium administration in rats increased tissue lipid peroxidation [18]. In agreement with the previous results, the current study revealed that the levels of LPO were significantly higher in cadmium group than control group in the tissues homogenates of testes. Aruld has reported that oxidative stress by free radical toxicity caused by cadmium affected infertility [19]. Stajn et al. reported that different doses of cadmium increase organ lipid peroxidation (LPO) in many organs including male sex organs and brought about changes in the antioxidant defense system [20].

Blanco et al. claimed that even with low doses of cadmium chloride (1mg/kg for one month) induced lack of spermatogenesis and severe necrosis of the testes of rats [21]. Moreover, Santos et al. reported that endothelial damage of the small blood vessels, edema and hemorrhage of the rat testes can be demonstrated by using just a single parenteral dose of cadmium chloride at 2-4 mg/kg [1]. The result of the present study showed histological changes like decreased spermatogenesis (less than 10% of tubule) and atrophy of the tubules

In the present study, pretreatment with vitamin E & Vitamin C in combination prior to cadmium administration showed a significant reduction in the levels of LPO compared to cadmium treated group. The levels of GSH & SOD in rats pretreated with vitamins prior to cadmium administration were significantly elevated in comparison with cadmium treated group. The present study also revealed the pretreatment with vitamin E & C in combination prior to cadmium administration showed the normal architecture of the testis. Hence, the result of the present study demonstrated the protective role of vitamin E & C in combination on cadmium chloride induced testicular damage.

CONCLUSION

The exposure of rats to cadmium chloride induces biochemical & histopathological effects in the testes. The increased oxidative stress resulted from cadmium intoxication in testicular tissue might be responsible, at least in part, for histopathological changes. Vitamin E & C in combination had protective effect against cadmium toxicity evidenced by reduction of LPO & increase in GSH and sod level as well as normal architecture of the testes in the rats treated with vitamin

REFERENCES

- [1] Santos FW, Oro T, Zeni G, Rocha JBT, Do Nascimento PC & Nogueira CW. *Toxicol Lett* 2004; 152:255-63.
- [2] Yu HN, Shen SR & Yin JJ. *Crit Rev Food Sci Nut* 2007; 47(8):711-9.
- [3] Oteiza PI, Adonaylo VN & Keen CL. *Toxicol* 1999; 137(1):13-22.
- [4] Shaikh ZA & Tang W. *Toxicol* 1999; 132(2):139-46.
- [5] Anders RJ Bergh. *Toxicol* 1990; 63: 183-186.
- [6] Kara H, Karatas F, Canatan H & Servi K. *Bio Trace Elem Res* 2005; 104(3):223-32.
- [7] Sato M & Takizawa Y. *Toxicol Lett* 1982; 11(3-4): 269-73.
- [8] Ronojoy Sen Gupta, Enakshi Sen Gupta, Bijaya Kumar Dhakal, Ashoke Ranjan Thakur, Joohong Ahnn. *Mol cells* 2004:17; 132-139.
- [9] Byung Pal Yu. *J Physiological Reviews* 1994; 7:134-163.
- [10] Halliwell B. *Free Rad Res* 1996; 25:439-454.
- [11] Kartha R, Krishnamurthy S. *I J Physiol Pharmacol* 1978; 22: 44-52.
- [12] Beutler E, Duron O, Kelly BM. *J Lab Clin Invest* 1963; 61: 883-887.
- [13] Beauchamp C, Fridovich I. *Ann Biochem* 1971; 44: 276-287.
- [14] Culling CFA, Allison RT, Batt WT. *Cellular pathology techniques*, 14th ed. Butter worths, 1985.
- [15] Mueller L. *Toxicol* 1986; 40:285-95.
- [16] Bagchi D, Bagchi M, Hassoun EA & Stohs SJ. *Biol Trace Elem Res* 1996; 52:143-54.
- [17] El-Maraghy SA, Gad MZ, Fahim AT & Hamdy MA. *J Biochem Mol Toxicol* 2001; 15(4):207-14.
- [18] Xiao P, Jia XD, Zhong WJ, Jin XP & Nordberg G. *Biomed Environ Sci* 2002; 15:67-74.
- [19] Aruldas MM, Subramanian S, Seker P, Vengatesh G, Chandrahasan G, Govindarajulu P & Akbarasha MA. *Hum Reprod* 2005; 20:2801-13.



- [20] Stajn A, Zikic R, Ognjanovic VB, Saicic ZS, Pavlovic SZ, Kostic MM & Petrovic VM. *Comp Biochem Physiol C Pharmacol Toxicol Endocrinol* 1997; 117C:167-72.
- [21] Blanco A, Moyano R, Vivo J, Flores-Acuña R, Molina A, Blanco C, Agüera E & Monterde JG. *Environ Toxicol Pharmacol* 2007; 23:96-101.