



Research Journal of Pharmaceutical, Biological and Chemical Sciences

Neural Tube Defects In North Coastal Andhra Pradesh

M Pramila Padmini*, B Narasinga Rao

Department of anatomy, Maharajah's Institute of Medical Sciences. Nelli marla.

ABSTRACT

Neural tube defects (NTD) are one of the most common structural congenital anomalies. The defects include spina bifida, anencephaly (absence of brain calvaria, total or partial), encephalocele (herniation of brain and meninges through defect in calvaria), craniorachischisis (anencephaly associated with continuous bony defect of spine and exposure of neural tissue) and iniencephaly (dysraphism of occipital region accompanied by retroflexion of neck and trunk). In the present study, out of 100 still born fetuses, 15 fetuses had neural tube defects. 7 fetuses were anencephalics, 3 had craniorachischisis, 4 had meningoceles and 1 had anencephaly associated with cervical meningocele. Folic acid deficiency causes neural tube defects. People of rural areas should be educated enough about folic acid intake and its relation to neural tube defects. Counseling regarding folic acid supplementation is essential for all women of reproductive age

Key words : anencephaly, craniorachischisis, meningocele, neural tube

**Corresponding author:*

E-mail: mini141@yahoo.com



INTRODUCTION

Neural tube defects (NTD) are one of the most common structural congenital anomalies. The spectrum includes spina bifida, anencephaly (absence of brain calvaria, total or partial), encephalocele (herniation of brain and meninges through defect in calvaria), craniorachischisis (anencephaly associated with continuous bony defect of spine and exposure of neural tissue) and iniencephaly (dysraphism of occipital region accompanied by retroflexion of neck and trunk) [1]. Epidemiological studies provide an opportunity to identify risk factors for neural tube defects, such as dietary or teratogenic agents, to which susceptibility may be modified by genetic predisposition [2-4] . Among environmental factors, folate status plays a key role in determining NTD risk [5, 6] . Maternal supplementation with folic acid during pregnancy reduces NTD frequency [7, 8] .Gene–environment interactions appear likely to contribute to NTD predisposition, with examples including interactions of MTHFR with multivitamin use [9].

Anencephaly

Anencephaly is a defect in the closure of the neural tube during fetal development. The neural tube is a narrow channel that folds and closes between the 3rd and 4th weeks of pregnancy to form the brain and spinal cord of the embryo. Anencephaly occurs when the "cephalic" or head end of the neural tube fails to close, resulting in the absence of a major portion of the brain, skull, and scalp. Infants with this disorder are born without a forebrain (the front part of the brain) and a cerebrum (the thinking and coordinating part of the brain)[10].

Spina Bifida

Spina bifida (Latin: "split spine") is a developmental congenital disorder caused by the incomplete closing of the embryonic neural tube. Some vertebrae overlying the spinal cord are not fully formed and remain unfused and open. If the opening is large enough, this allows a portion of the spinal cord to protrude through the opening in the bones. There may or may not be a fluid-filled sac surrounding the spinal cord. Spina bifida malformations fall into four categories: spina bifida occulta, spina bifida cystic (myelomeningocele), meningocele and lipomeningocele [11].

Spina bifida occulta is the mildest form of spina bifida and is often called hidden spina bifida. In spina bifida occulta, at least one vertebra is malformed, but the nerves and spinal cord are normal and are covered by a layer of skin. Approximately 5 to 10 percent of the population is believed to have spina bifida occulta [12].

Meningocele involves the meninges, the membranes responsible for covering and protecting the brain and spinal cord. If the meninges push through the hole in the vertebrae (the small, ring-like bones that make up the spinal column), the sac is called a meningocele [13].

Myelomeningocele is the most severe form of spina bifida. It occurs when the meninges push through the hole in the back, and the spinal cord also pushes through. Most babies who

are born with this type of spina bifida also have hydrocephalus, an accumulation of fluid in and around the brain [13].

Craniorachischisis

Craniorachischisis is a developmental defect that occurs during the fetal gestation period. It is characterized by malformation of the skull and spinal bone which results in exposure of the brain and nerves. The cause of craniorachischisis is due to failure of the neural tube to close during the early stages of fetal development; about the third to fourth week of the gestation period [14].

CASE REPORT

The still born fetuses were brought to the department of anatomy, MIMS medical college as a part of the project work. Out of 100 fetuses collected from local government and private hospitals in vizianagaram, nellimarla, 15 fetuses had neural tube defects 7 fetuses are anencephalics, 3 with craniorachischisis, 4 with meningoceles and 1 with anencephaly associated with cervical meningocele.

A 27 year old female was asked to get her ultrasound scanning during 28weeks of gestation. Scan revealed a female foetus with anencephaly (absence of brain) leaving a small part of brain stem. Pregnancy was terminated at the same gestational age. The appendicular skeleton and axial skeleton were normal except for the neurocranium which was absent (fig.1)

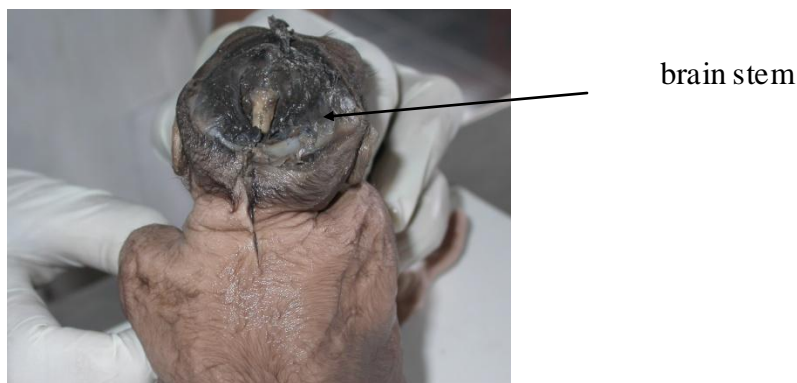


Fig.1 Showing Anencephalic Fetuses With Absence Of Brain ,Leaving A Stalk Of Brain Stem

During a routine scan for a 30 year old female , revealed a female fetus with craniorachischisis and pregnancy was terminated at 28 weeks of gestation. The still born fetus showed absence of cranial bones covered by skin and entire vertebral spines are malformed exposing the split spinal cord (myeloschisis) and spinal nerves(fig.2).

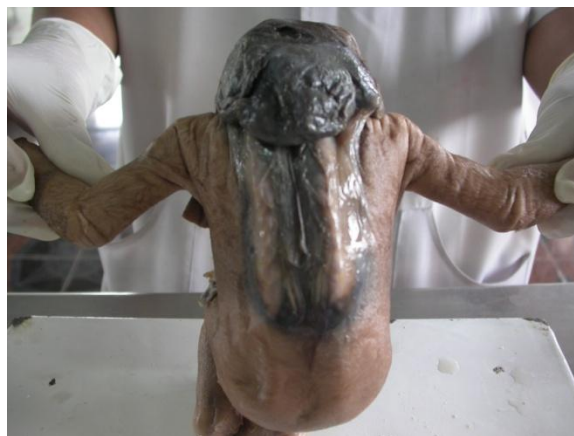

Fig.2 Showing Split Spinal Cord And Spinal Nerves In Malformed Vertebral Column

A still born female foetus with sacral meningocele is delivered by a female of 32 years at 34 wks of gestation. The foetus presented a sacral meningocele containing fluid filled cyst without the involvement of spinal cord.(fig.3)

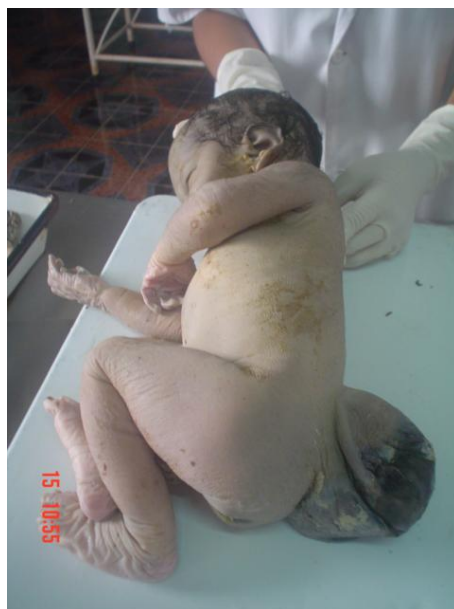

Fig.3 Showing Sacral Meningocele

A 25 year old female from a rural area was asked to get her ultrasound scanning during 32 weeks of gestation. The scan revealed a female foetus with cervical meningocele . pregnancy was terminated. The foetal abnormalities observed were gastroschisis(abdominal viscera protruding through the anterior abdominal wall), anencephaly and cervical meningocele (fig.4).

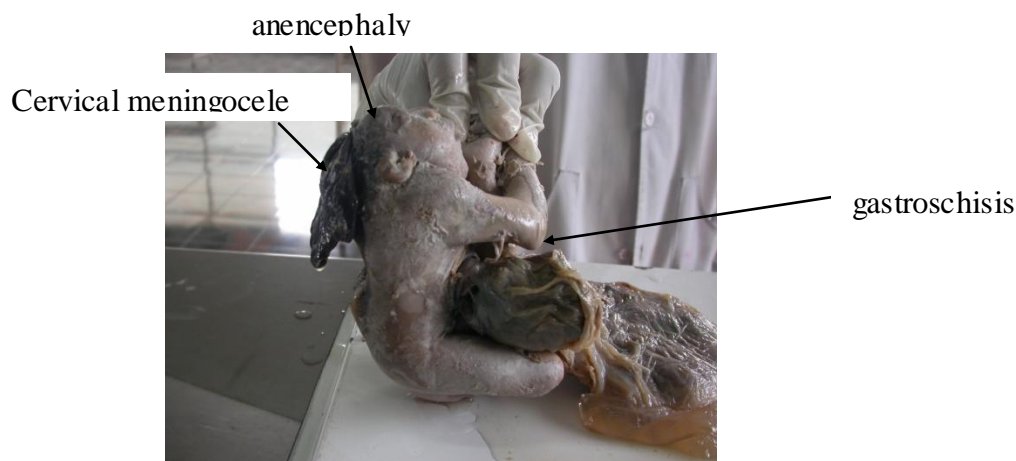


Fig.4 Showing Gastroschisis, Anencephaly And Cervicalmeningocele

DISCUSSION

The entire nervous system develops from an infolding of the outer embryonic layer. This outer layer also gives rise to skin [15]. The developmental process of neurulation involves a series of coordinated morphological events, which result in conversion of the flat neural plate into the neural tube, the primordium of the entire central nervous system (CNS). Failure of neurulation results in neural tube defects (NTDs), severe abnormalities of the CNS, which are among the commonest of congenital malformations in humans [16]. The cranial end of the neural tube becomes the forebrain, midbrain, and hindbrain, and a failure of closure results in anencephaly. The caudal end of the neural tube becomes the spinal cord, and a failure of posterior neuropore closure results in spina bifida [17]. The reported NTD incidence in India varies from 0.5 to 11/1000 births while the incidence in the USA and Europe is reportedly below 1/1000, with progressive decline with periconceptional folate fortification [18]. Empiric recurrence risk of NTDs rises from approximately 3% to 10% of the baseline population risk, if two offspring are affected [19]. Dinakar [20] from Andhra Pradesh in 1972 followed by Kulkarni, et al. [21] in 1989 have commented on consanguineous marriages in relation to the NTDs. In India the prevalence is 3.63/1000 live births, the highest reported from the northern states, namely Punjab, Haryana, Rajasthan and Bihar [22].

Several teratogens have been implicated in the cause of NTDs. Two anticonvulsant medications in current use, carbamazepine and valproic acid, have been demonstrated to cause these defects. Robert et al [23] originally reported an association between valproic acid and NTDs, noting a 1% risk for NTDs in patients taking this medication.

Folic acid or pteroylmonoglutamic acid is a B group vitamin, first isolated from spinach leaf in 1941 [24]. Due to greater bioavailability and ease of compliance with recommended intake, supplementation with the synthetic form of folic acid rather than dietary intervention is a more efficacious approach for prevention neural tube defects. As a result, the US Public

Health Service recommended in 1992 that all women of child-bearing age consume at least 400 µg of synthetic folic acid daily in addition to eating a folate-rich diet[25].

CONCLUSION

Study revealed that the underlying nutrient deficits and the genetic predisposition lead into neural tube defects. We found that more number of neural tube defects are occurring in rural areas. This may be due to improper medical education programmes in rural areas. People of rural areas should be educated enough about folic acid intake and its relation to neural tube defects. Counseling regarding folic acid supplementation is essential for all women of reproductive age.

REFERENCES

- [1] Hema Gupta, Piyush Gupta Indian Pediatrics 2004; 41:577-586, Neural Tube Defects and Folic Acid
 - [2] Frey L, Hauser WA Epilepsia 2003;44:4-13
 - [3] Mitchell LE. Am J Med Genet 2005; 135C: 88-94
 - [4] Carmichael SL, Witte JS, Shaw GM. Epidemiology 2009;20:67-73
 - [5] Blom HJ, Shaw GM, Den Heijer M, Finnell RH. Nat Rev Neurosci 2006;7:724-731
 - [6] Beaudin AE, Stover PJ. Birth Defects Res C Embryo Today 2007;81:183-203
 - [7] Smithells RW, Sheppard S, Schorah CJ, Seller MJ, Nevin NC, Harris R. Lancet 1980;1:339-340
 - [8] Wald N, Sneddon J, Densem J, Frost C, Stone R. Lancet 1991;338:131-137
 - [9] Volcik KA, Shaw GM, Lammer EJ, Zhu HP, Finnell RH. Birth Defects Res 2003; 67: 154-157
 - [10] <http://www.ninds.nih.gov/disorders/anencephaly/anencephaly.htm>
 - [11] http://en.wikipedia.org/wiki/Spina_bifida.
 - [12] <http://nervous-system.emedtv.com/spina-bifida-occulta/spina-bifida-occulta.html>
 - [13] http://kidshealth.org/parent/system/ill/spina_bifida.html
 - [14] <http://neuraltubedefect.com/craniorachischisis/>
 - [15] <http://faculty.stcc.edu/AandP/AP/AP1pages/nervssys/unit13/cns.htm>
 - [16] Greene ND, Copp AJ. Prenat Diagn 2009; 29(4): 303-11.
 - [17] Rose N, Mennuti, M, Glob. libr. women's med., (ISSN: 1756-2228) 2009; DOI 10.3843/GLOWM.10224
 - [18] Agarwal SS. Indian Pediatr 1999; 36: 643-648.
 - [19] Harper PS. Practical Genetic Counseling. London: Arnold Publishers; 2001
 - [20] Dinakar I. Indian J Med Sci 1972; 26: 440-442.
 - [21] Kulkarni ML, Mathew MA, Reddy V. Arch Dis Child 1989; 64: 201-204.
 - [22] Verma IC. Indian J Pediatr 2000; 67: 893-898
 - [23] Robert E, Guibaud P. Lancet 1982; 2: 937.
 - [24] Mitchell HK, Snell EE, Williams RF. J Am Chem Soc 1994; 66: 267-268.
- Centers for Disease Control: Recommendations for the use of folic acid to reduce the number of cases of spina bifida and other neural tube defects. MMWR Morb Mortal Wkly Rep 1992; 41(no. RR-14):1-7